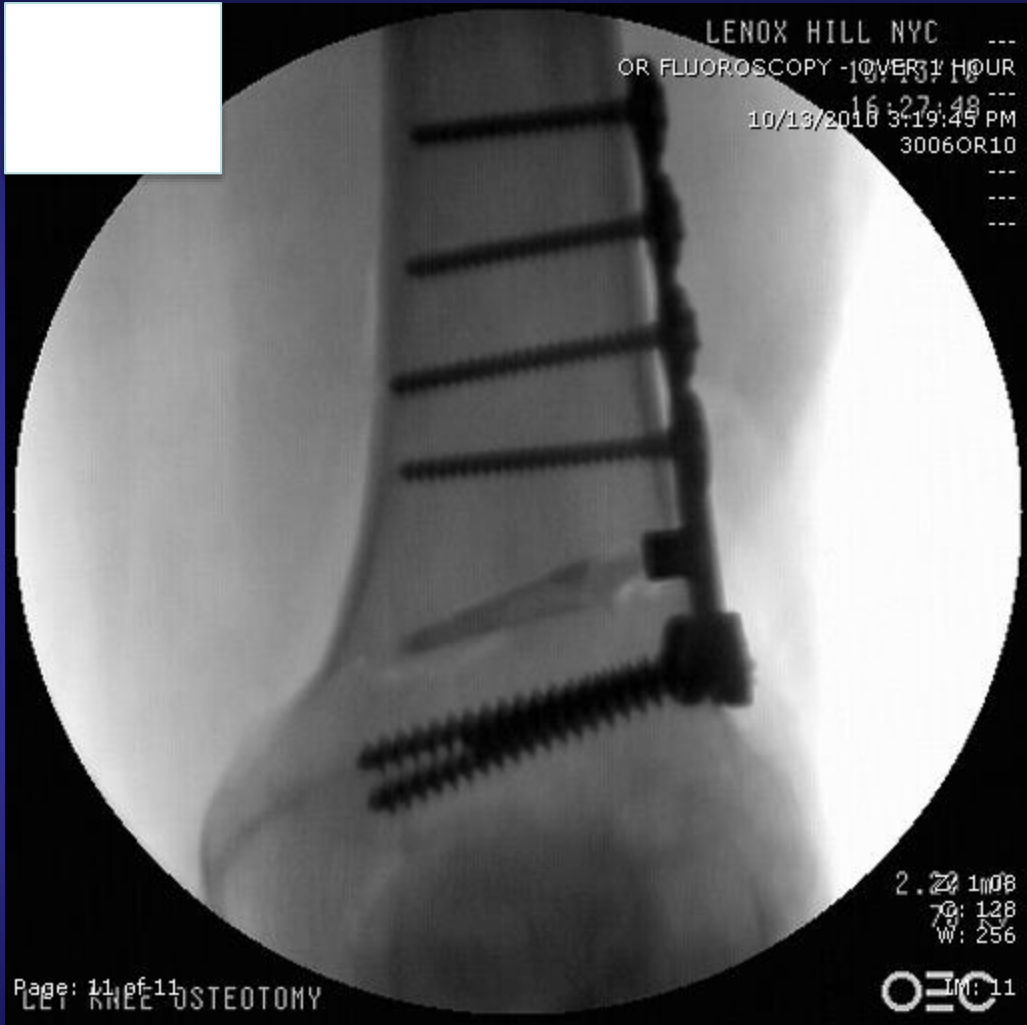



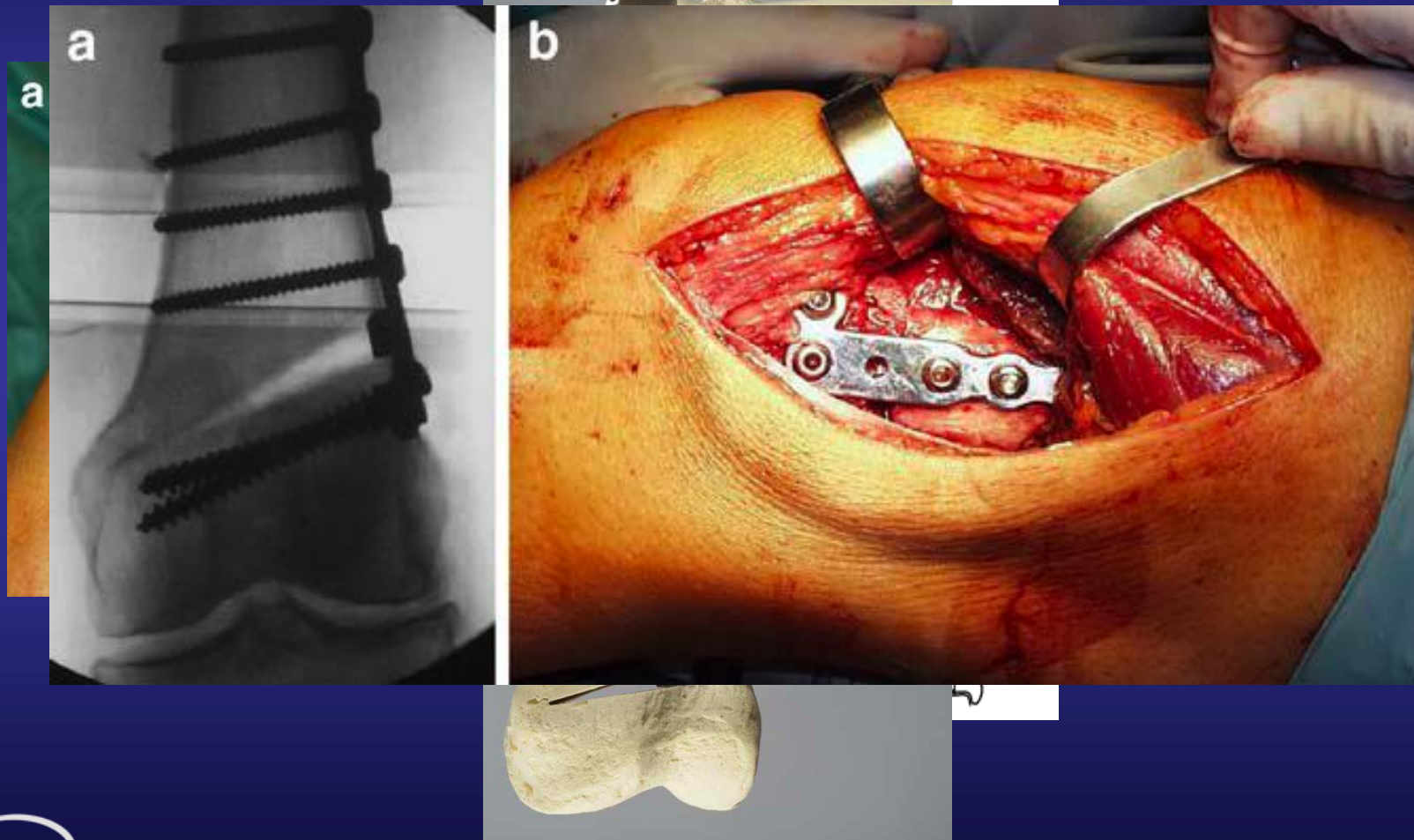
LENOX HILL NYC ---
OR FLUOROSCOPY - 10/13/2010
16:27:48
10/13/2010 3:19:49 PM
3006OR10

2.2 1108
70: 128
W: 256

OEC IM: 11

Page: 11 of 11
LET KNEE OSTEOTOMY

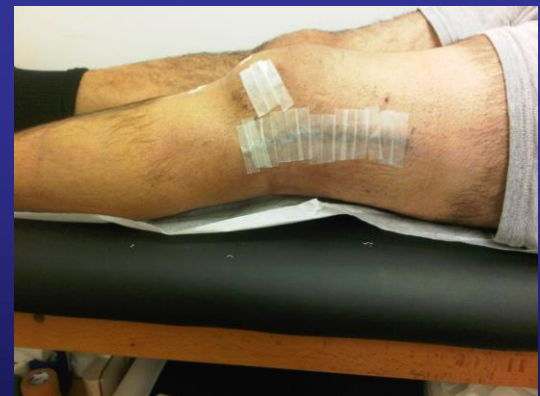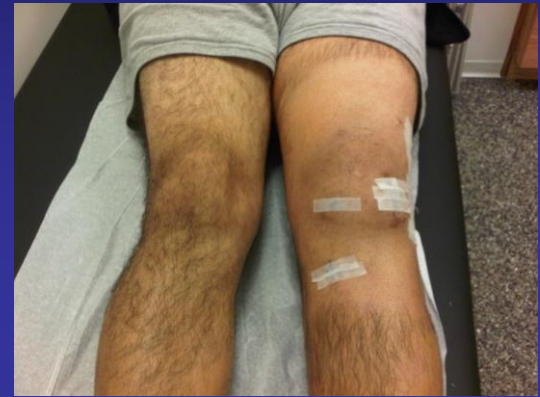Operative Procedure DFVO



82

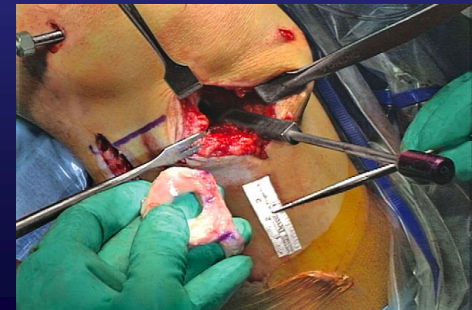Post Operative – 1 week

- 10/20/10
 - Incisions well healed
 - Staples removed, Steri's placed
 - ROM 0-90 degrees
 - TTWB in Bledsoe brace



Lateral Meniscal Transplant

- Noyes et al, *JBJS* 2005
 - Prospective study
 - 38 pts <50 y/o s/p meniscal transplant w/ cryopreserved meniscus
 - Avg age 30 y/o
 - Avg f/u 40 Months (24-69M)
 - Results:
 - **34/38 (89%) rated knee as improved**
 - Preop 79% had pain w/ ADL's vs. post op only 11%
 - 68% had no pain, 33% had only mild pain
 - 29/38 (76%) returned to low-impact sports
 - Complications:
 - 5 repeat arthroscopies for meniscal tears
 - 1 converted to TKA at 35 months

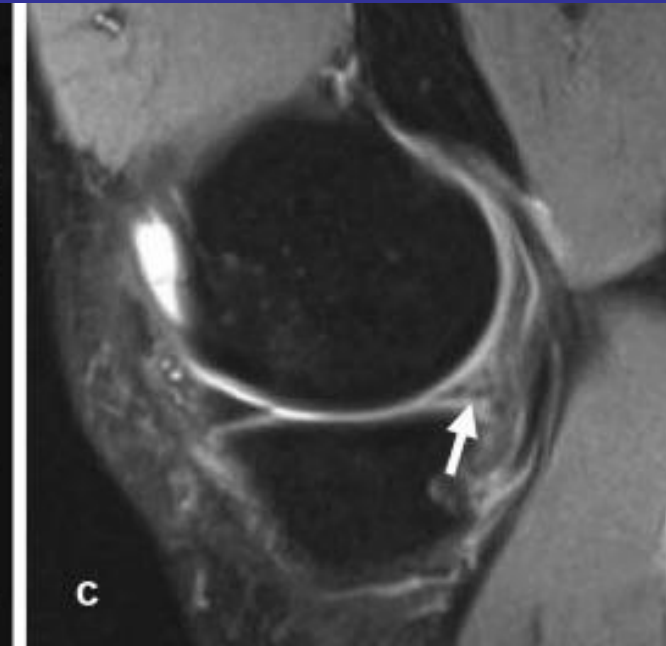

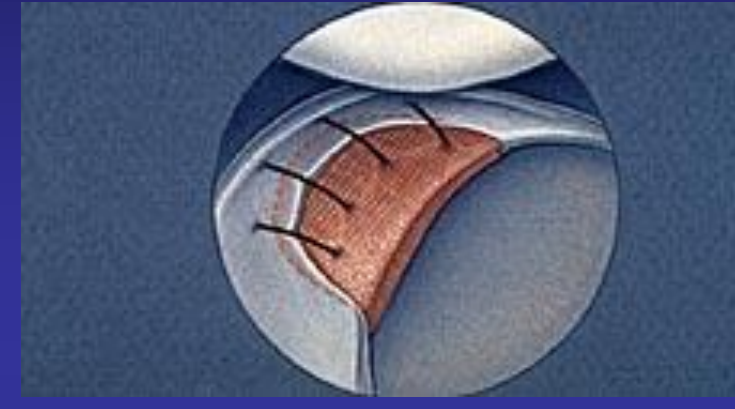
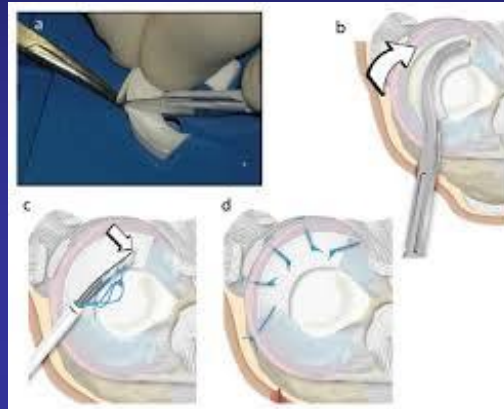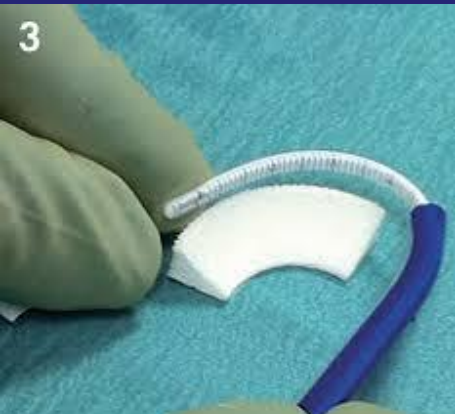



Synthetic Meniscus

Two Broad Categories

- For partial meniscectomy
 - Porus implants
 - Collagen Meniscal Implant
 - Actifit
 - FibroFix (Silk)
- For Total Meniscectomy
 - Non Porus
 - NU Surface
 - Polycarbonate Urethane (PCU)
 - TRAMPOLLIN
 - Anatomically shaped
 - Nonresorbable

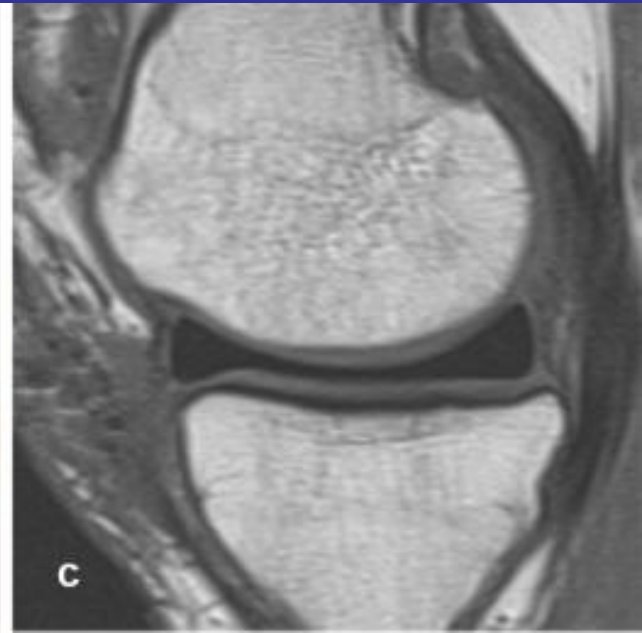
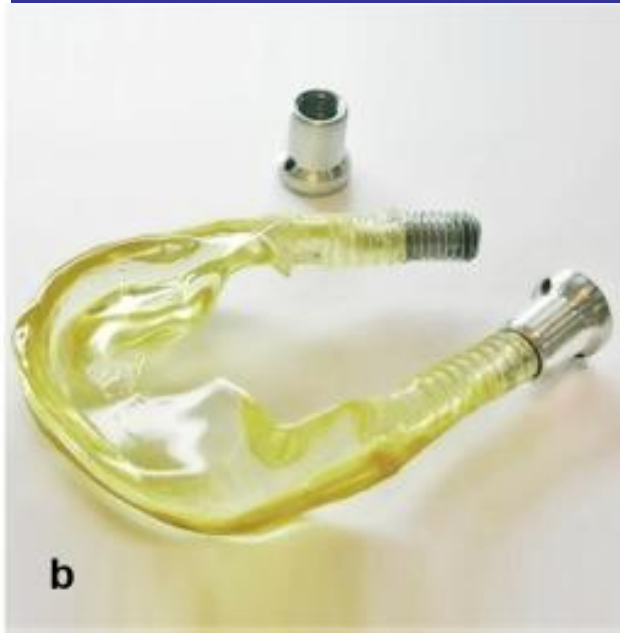
Collagen Meniscus Implant





Highly porous scaffold made from a biocompatible, slowly degrading
aliphatic polyurethane

NuSurface



Thank You