

**Sri Lanka Medical Association
– North America**

**2011 – Continuing Medical
Education Program**

November 12th, 2012

**New York Hilton, New York
USA**

SLMANA—Continuing Medical Education Committee (2011):

- **Sunil Wimalawansa, MD (Chairperson)**
- **Selvarani Richards, MD (Co-Chair)**
- **Aruna Seneviratne, MD**
- **Rohan Perera, MD**
- **Darshi Sunderam, MD**

SLMANA

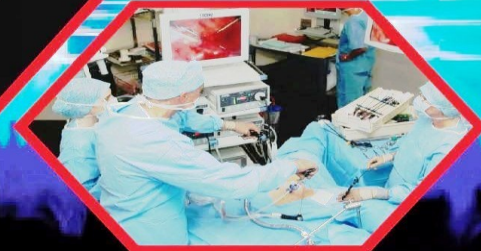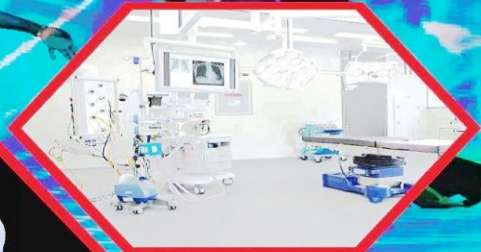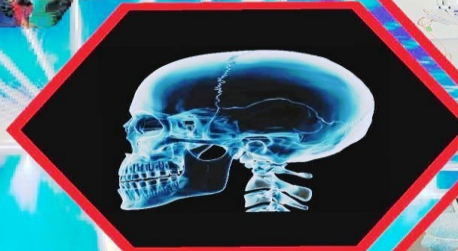Scientific Session – II

November 12th, 2011

Q & A

ANKA MEDICAL ASSOCIATION OF NORTH AMERICA
EASTERN REGION INC.
PRESENTS

**SLMANA EAST
CHARITY BALL
ANNUAL GENERAL MEETING
&
SCIENTIFIC SESSIONS
ON
NOVEMBER 12TH, 2011**

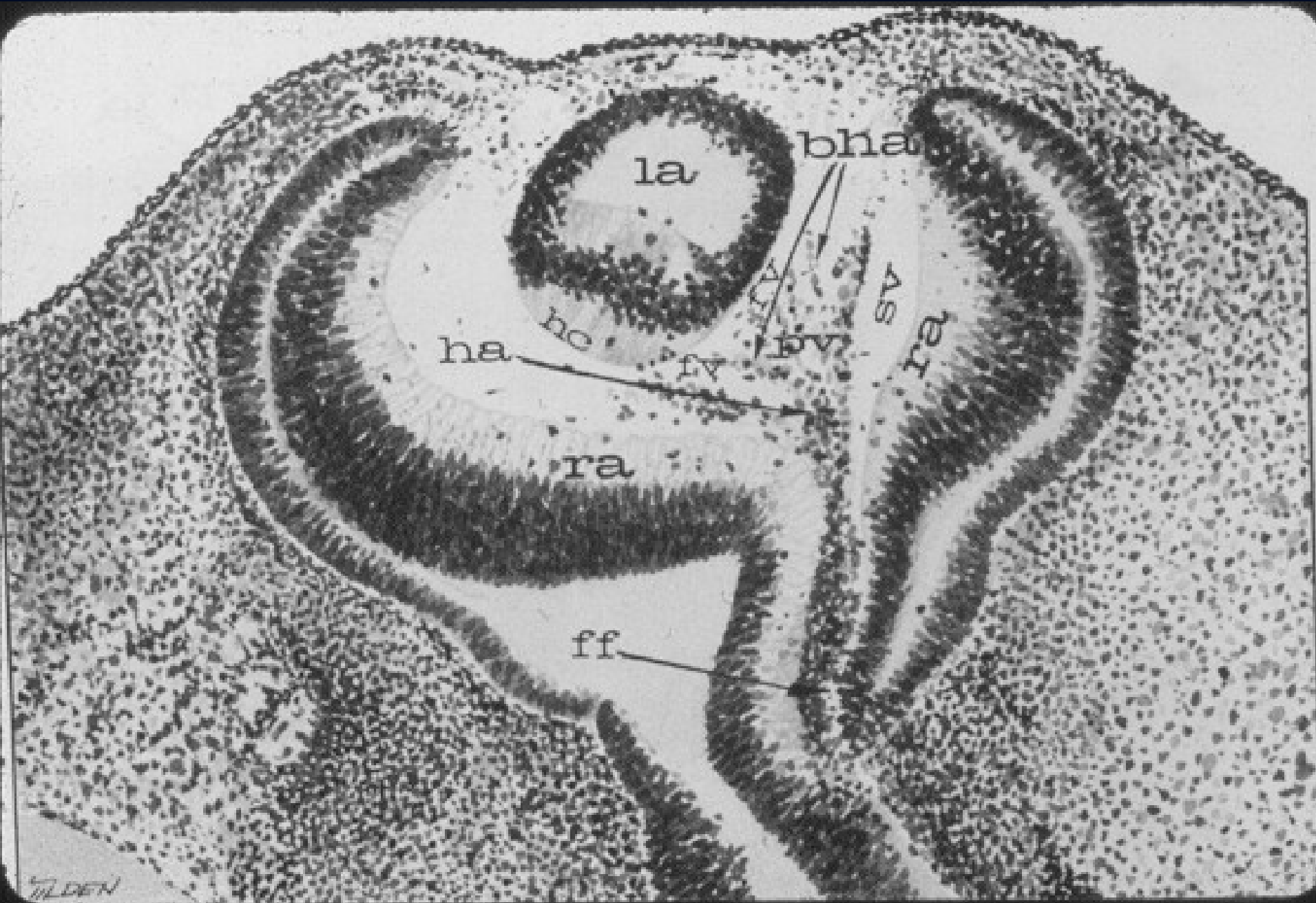


NEW YORK HILTON AND TOWERS
1335 Avenue of The Americas New York, NY

Ophthalmological Manifestations of Some General Medical Conditions



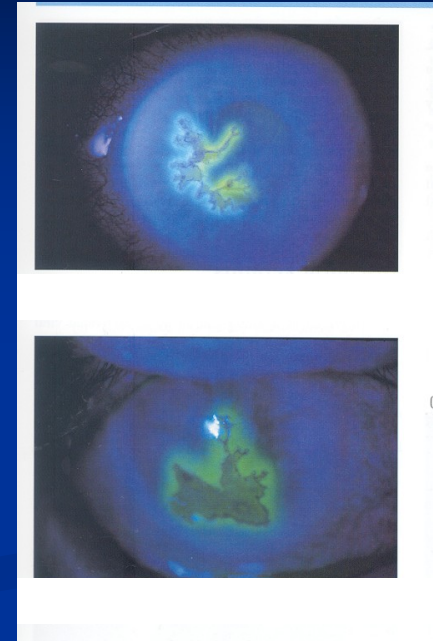
**UPALI ATURALIYA MD FRCS (ENG)
RELF EYE ASSOCIATES: DULUTH, MN**



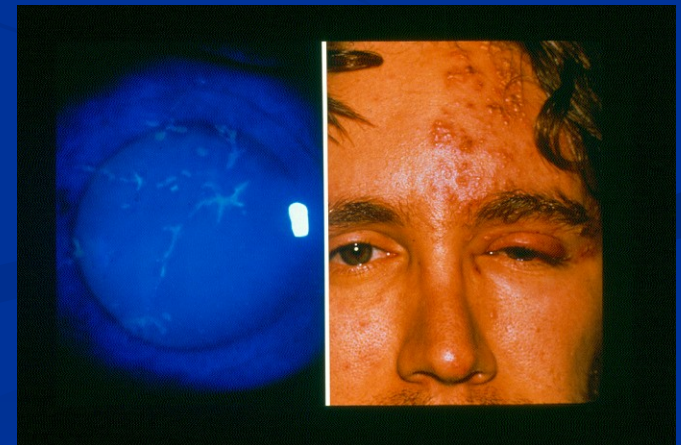
ALDEN

External Eye

- Herpes Simplex

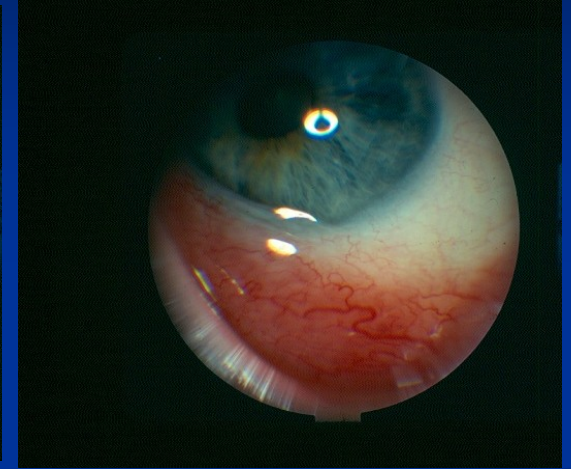
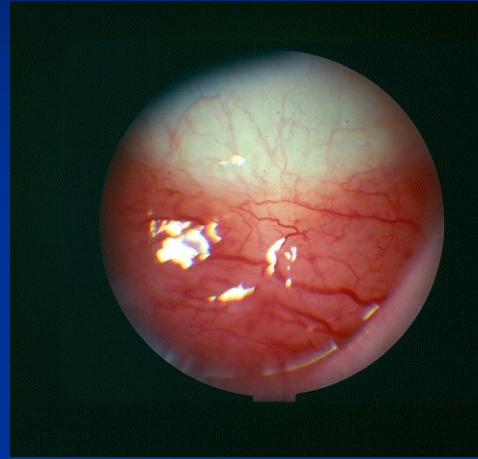


- Herpes Zoster

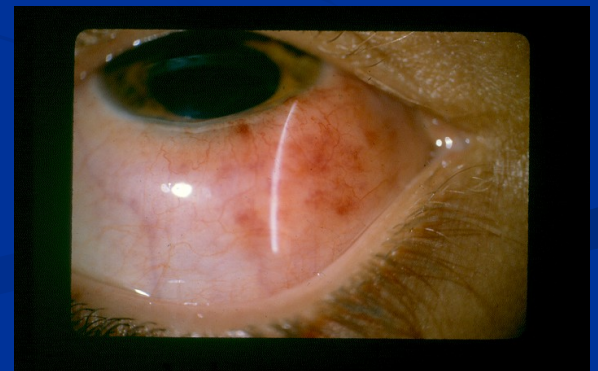
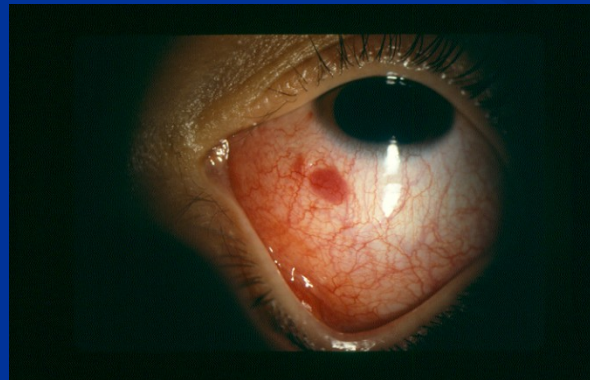


External Eye

- Lymphoma

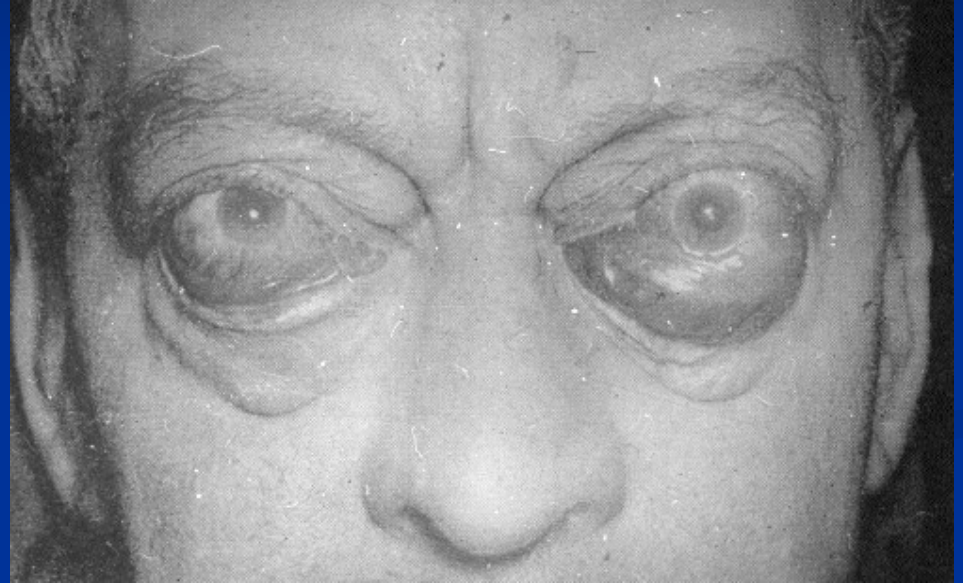

- Leukemia



Dysthyroid Ophthalmopathy

- Early symptoms
- Late symptoms



Definition

- **The autoimmune inflammatory disorder of the orbit associated with a thyroid metabolic abnormality**
- **Hyperthyroidism (90%)**
- **Euthyroid (6%)**
- **Hashimoto's thyroiditis (3%)**
- **Hypothyroidism (1%)**

Statistics

- **Female:Male 4:1**
- **Incidence 16/100,000/year in women and 3/100,000 in men**
- **The most common cause of unilateral and bilateral proptosis in adults**
- **Eye disease may precede the glandular disease**

Pathogenesis

- **TSH-R antibodies bind to the orbital fibroblast and preadipocyte causing them to produce hyaluronic acid, glycosaminoglycans, cytokines**
- **Activated T and B lymphocytes, plasma cells, mast cells product other inflammatory mediators (TNF-alpha, IL-1,2 and the interferon)**
- **The circulating autoimmune may be a marker for disease activity**
- **The autoimmune defect is inherited**

Two Phases of the Disease

- **Active inflammatory**

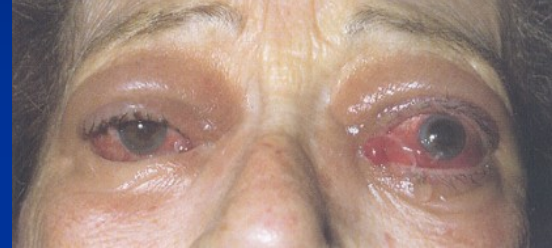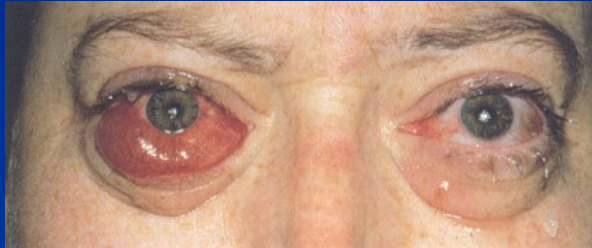- EOM's, orbital fat, skin of lids and brows, SOOF and ROOF all increase in volume
 - Increased vascularity

- **Inactive**

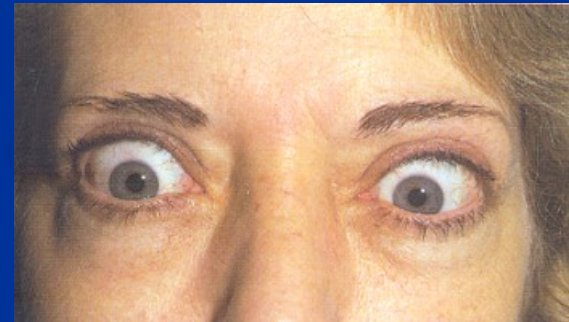- Inflammation replaced by fibrosis and scar in two years

Main Clinical Manifestations

1. Soft tissue involvement

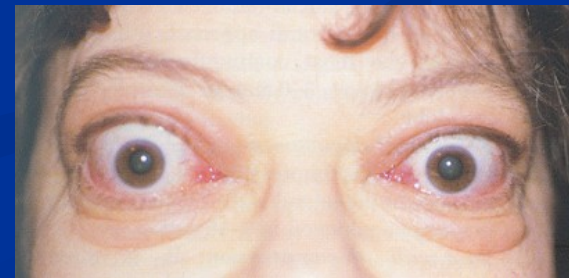

2. Eye-Lid Retraction



3. Proptosis

- Exposure Keratitis

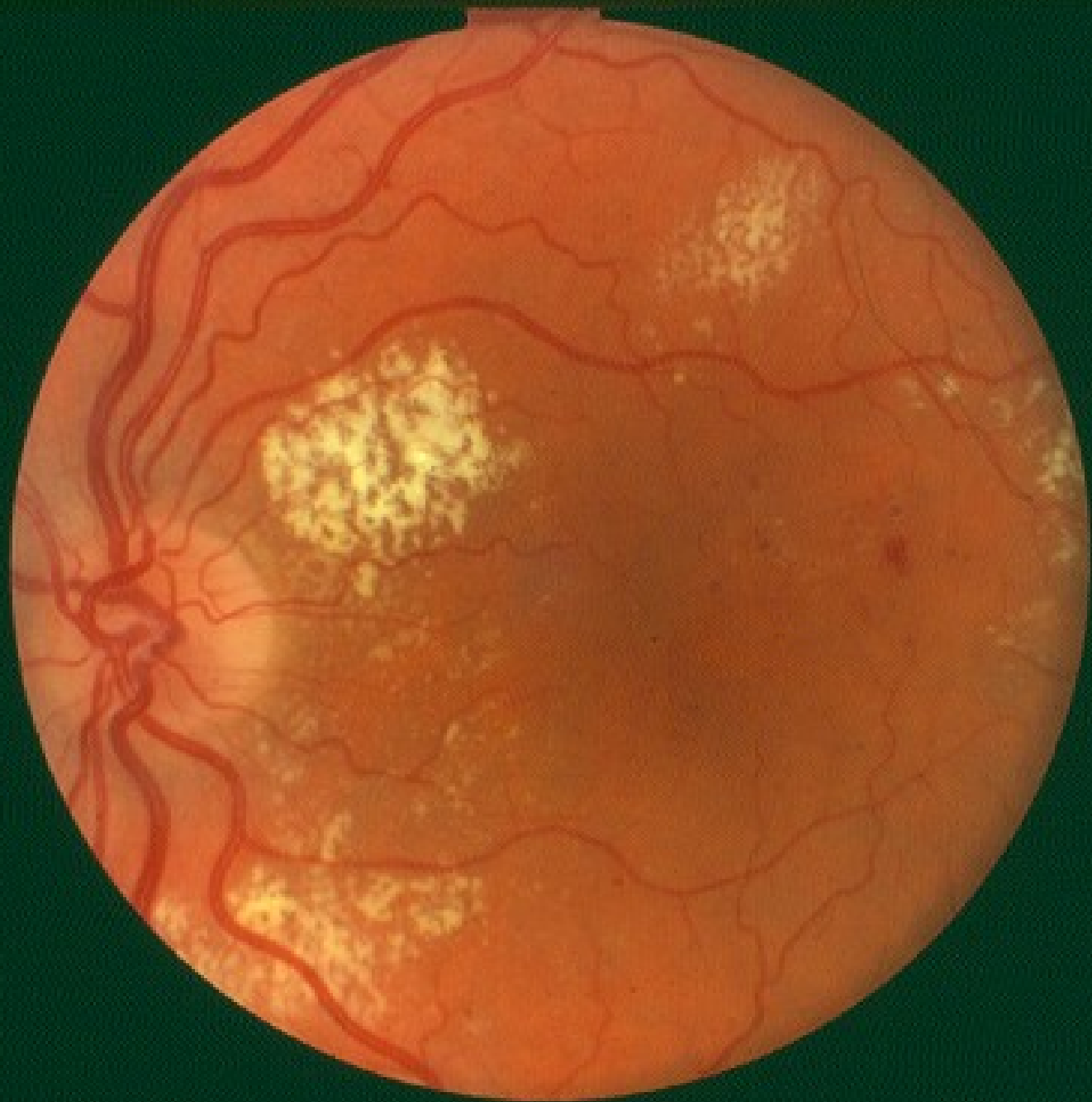

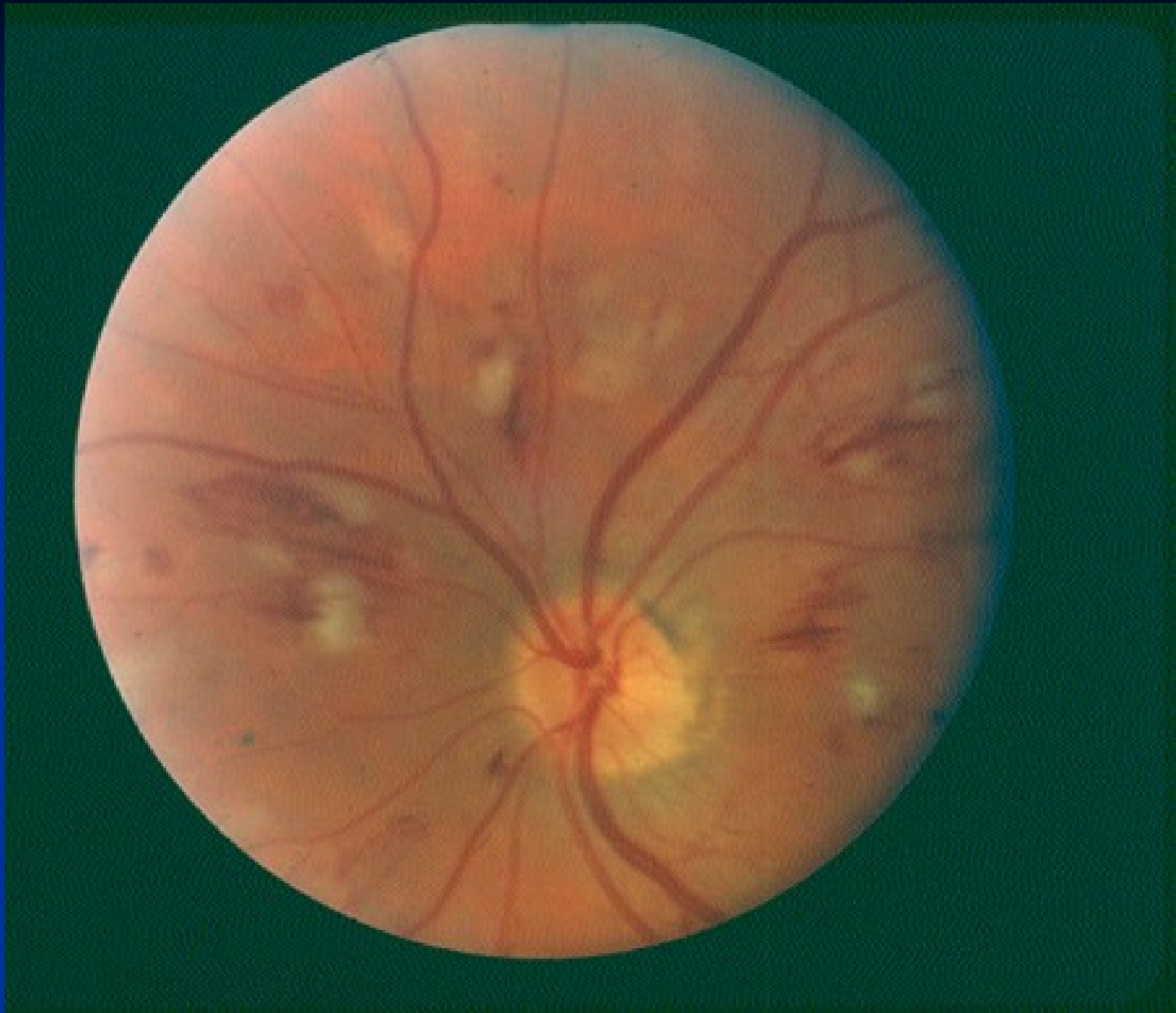Main Clinical Manifestations

- 4. Optic Neuropathy**
 - follow with visual fields
- 5. Restrictive Myopathy**

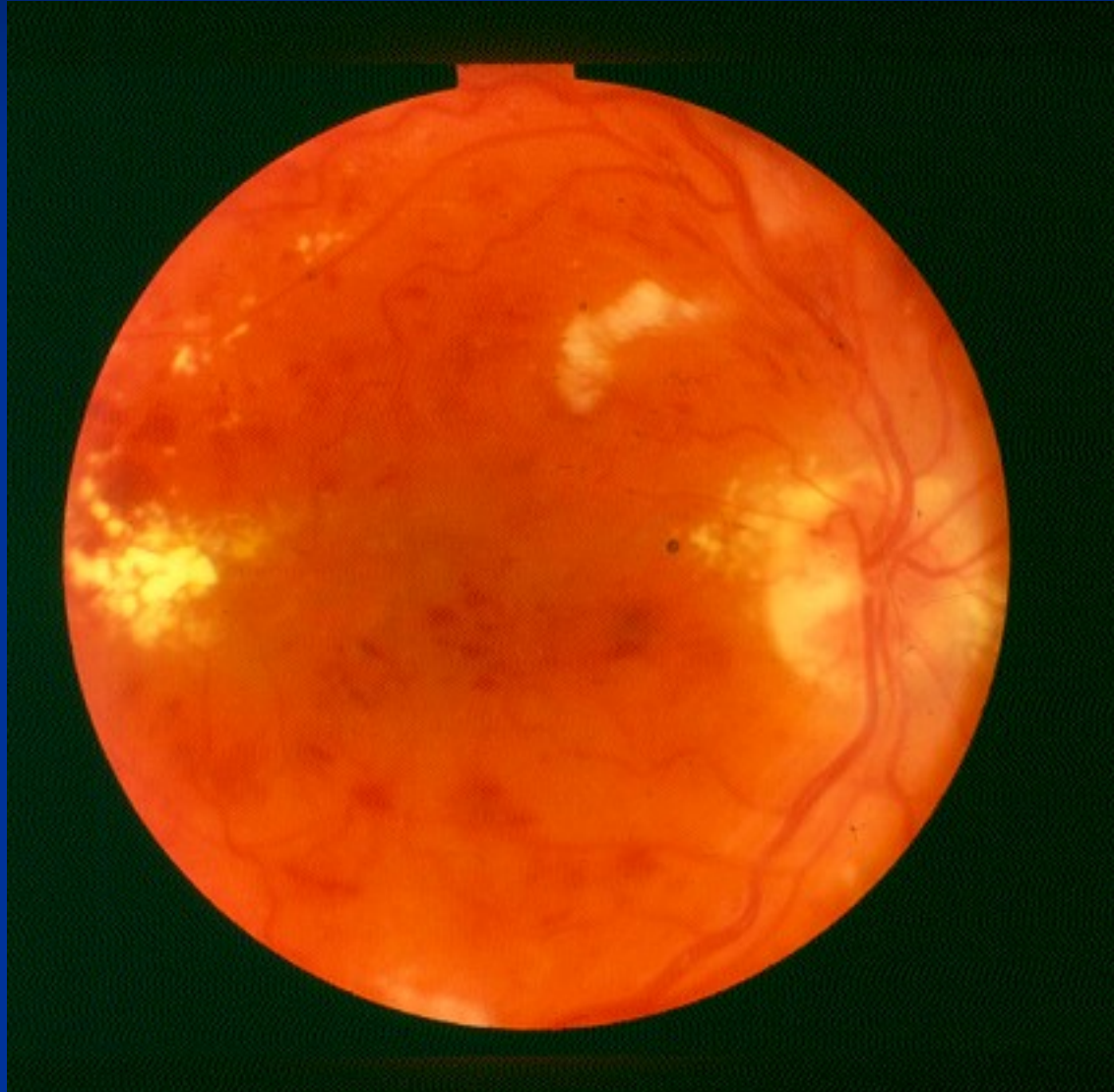
Diabetes Mellitus

- **Non proliferative diabetic retinopathy**
- **Proliferative diabetic retinopathy**



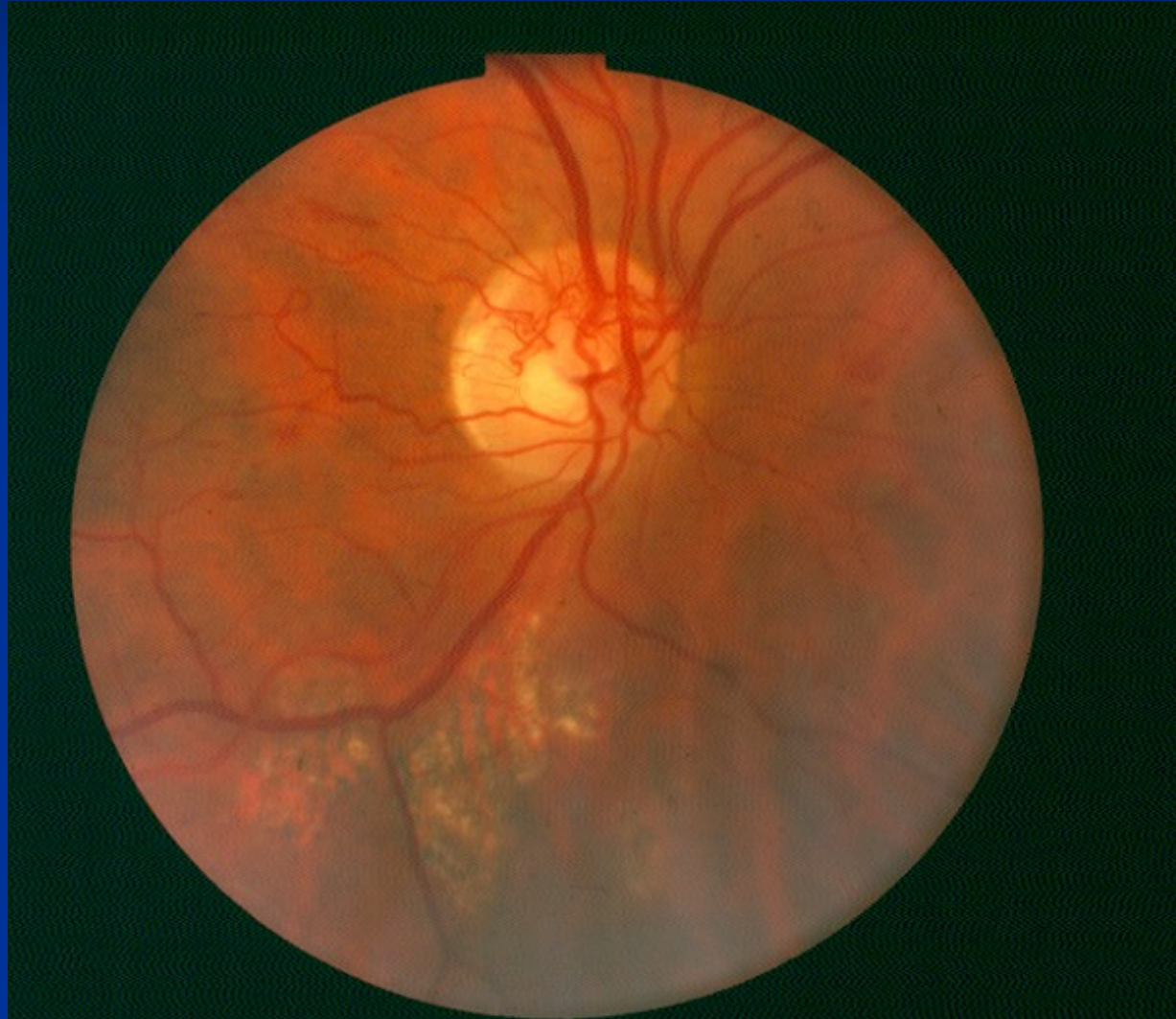


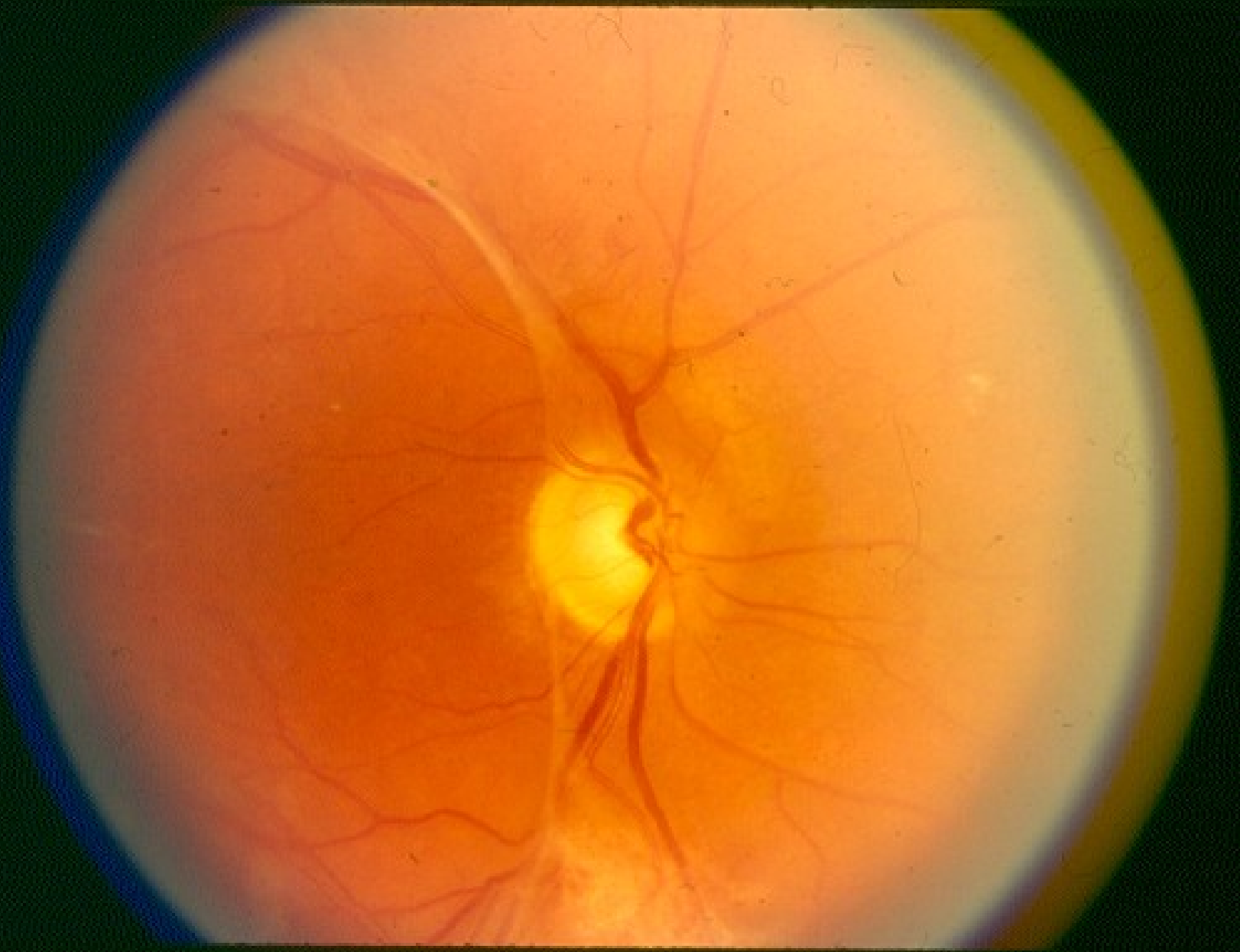
Background Retinopathy with Macular Edema (CME)

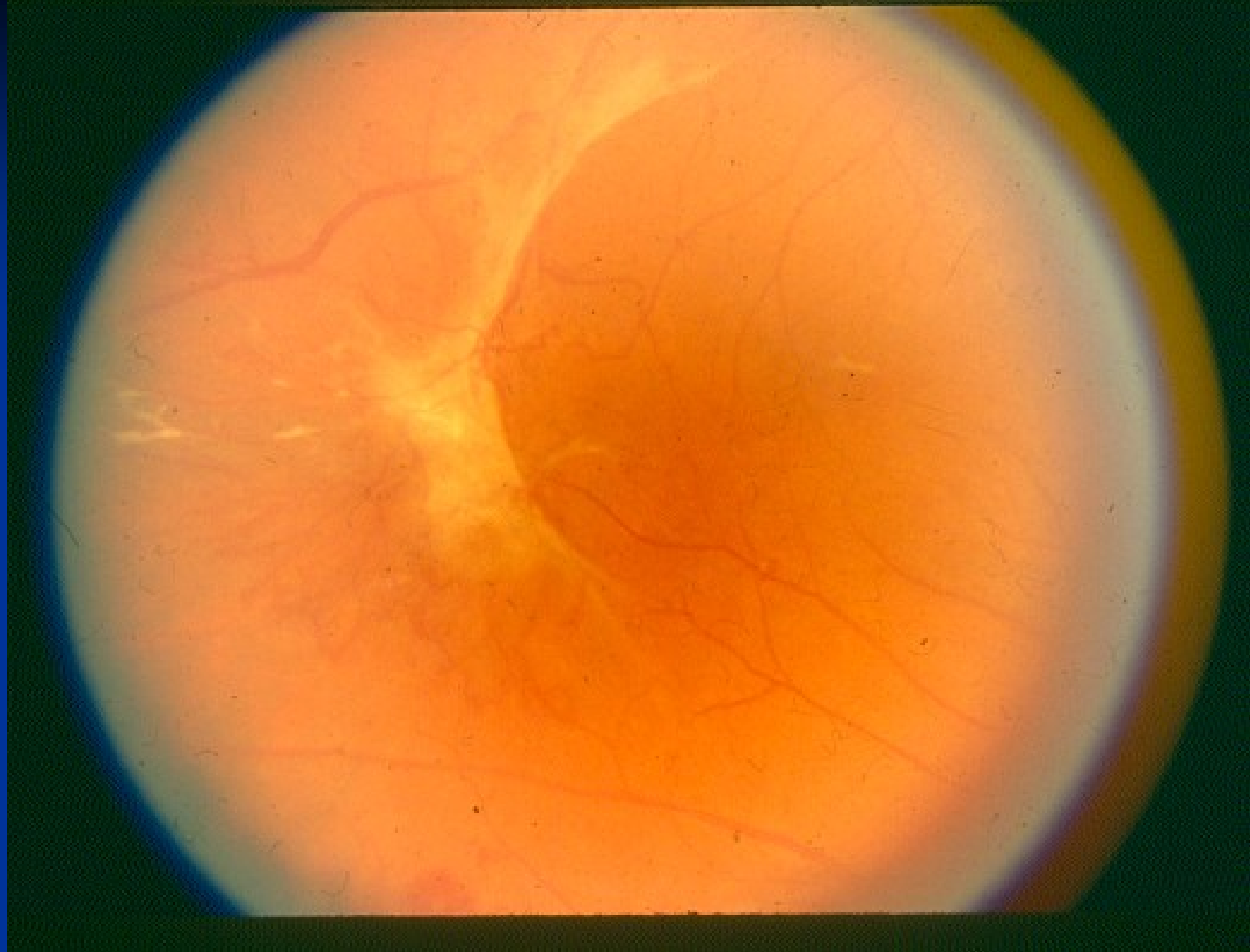


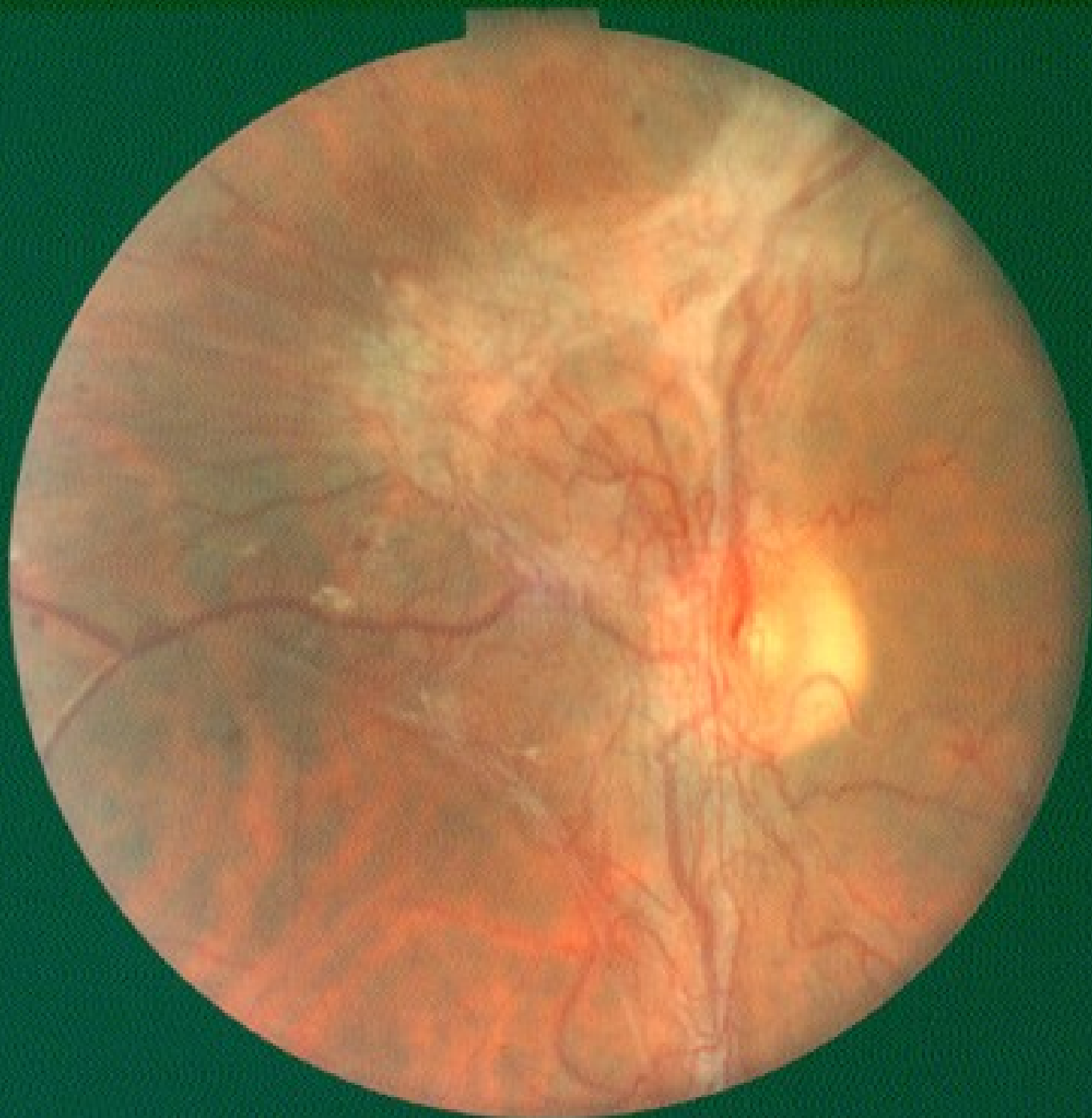Proliferative Diabetic Retinopathy

- **Early proliferative changes**
 - **Disc proliferation**



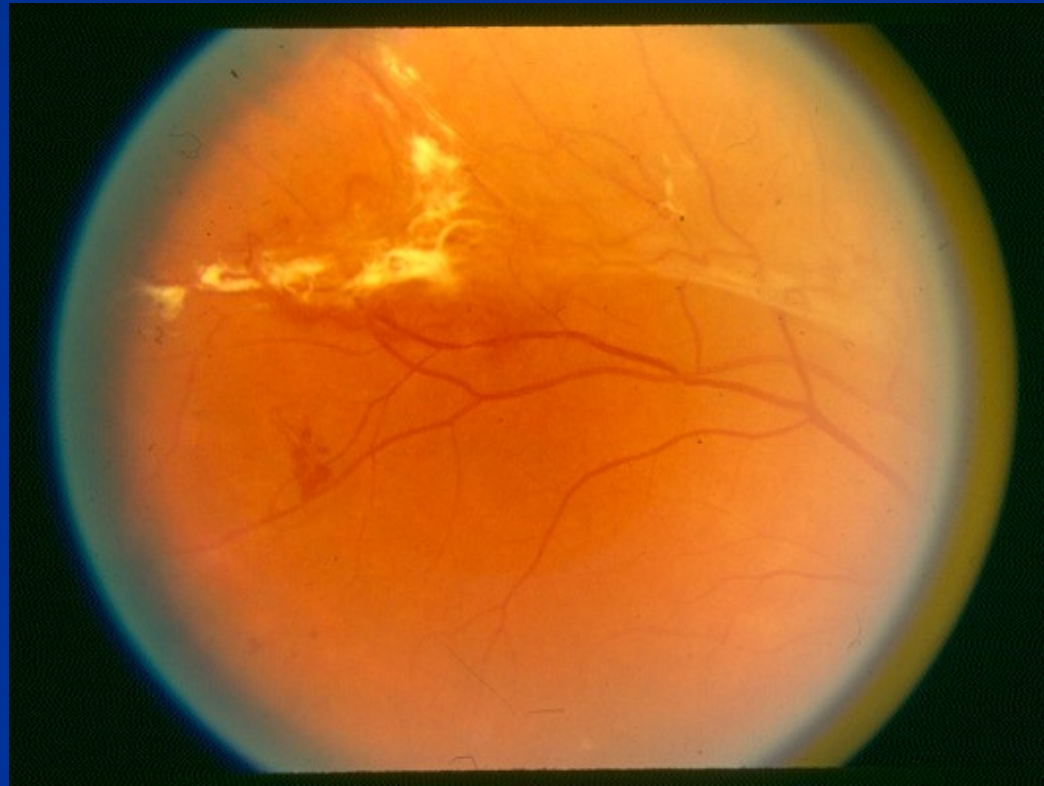






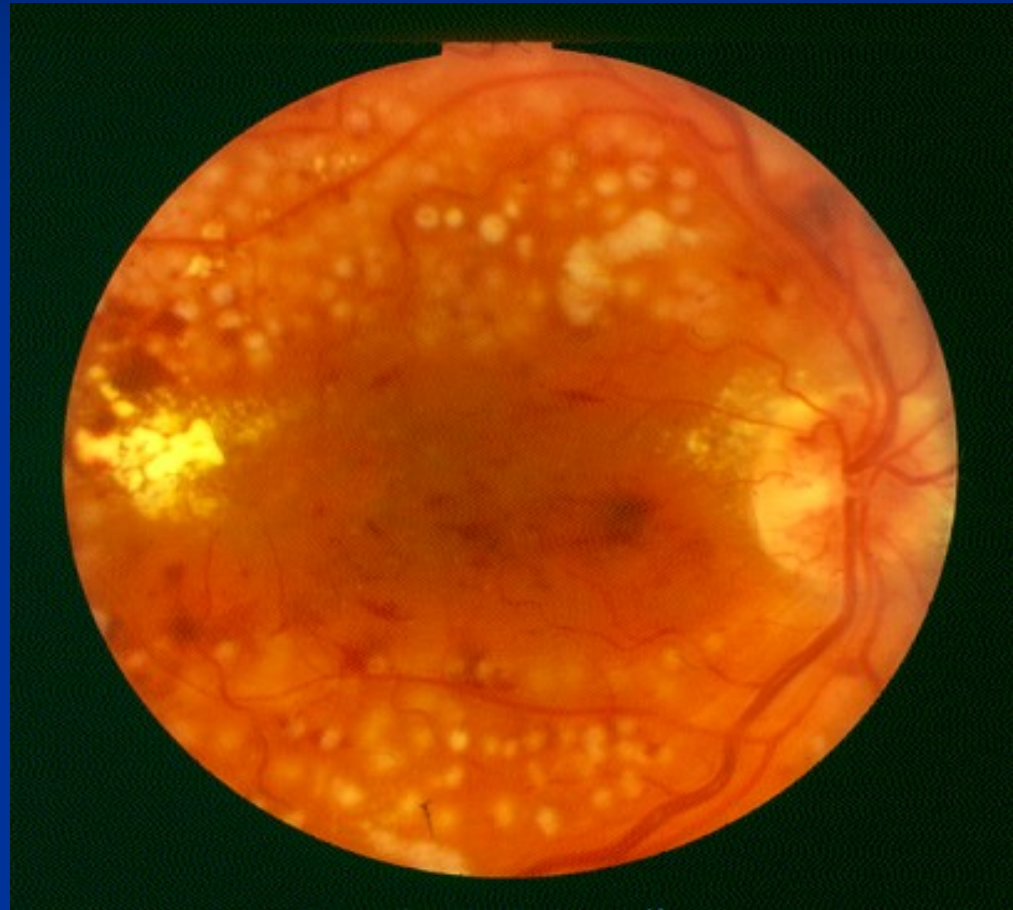Proliferative Diabetic Retinopathy

- **Early proliferative changes**
 - **Non-disc proliferation**

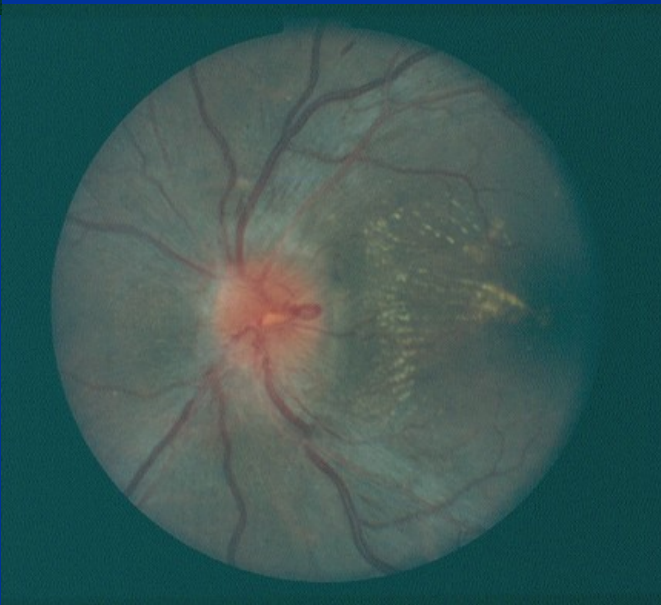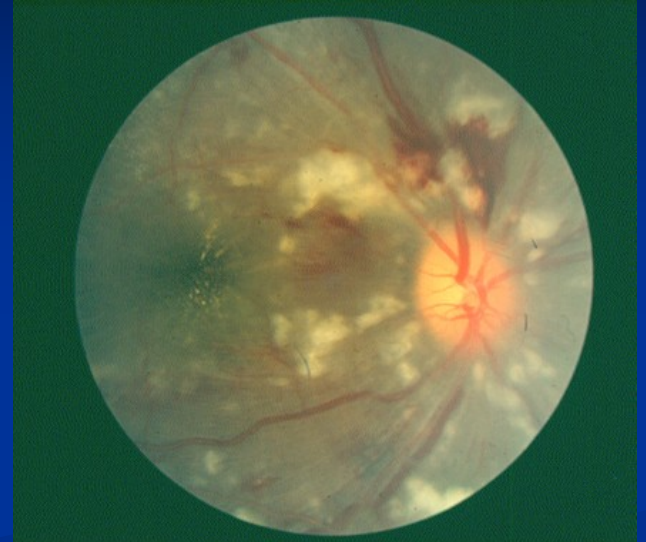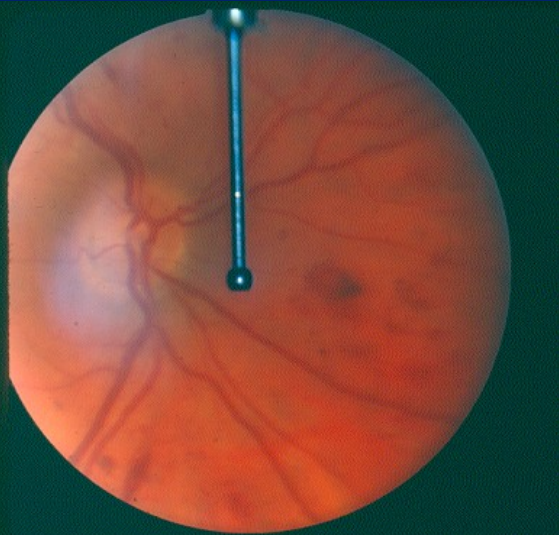


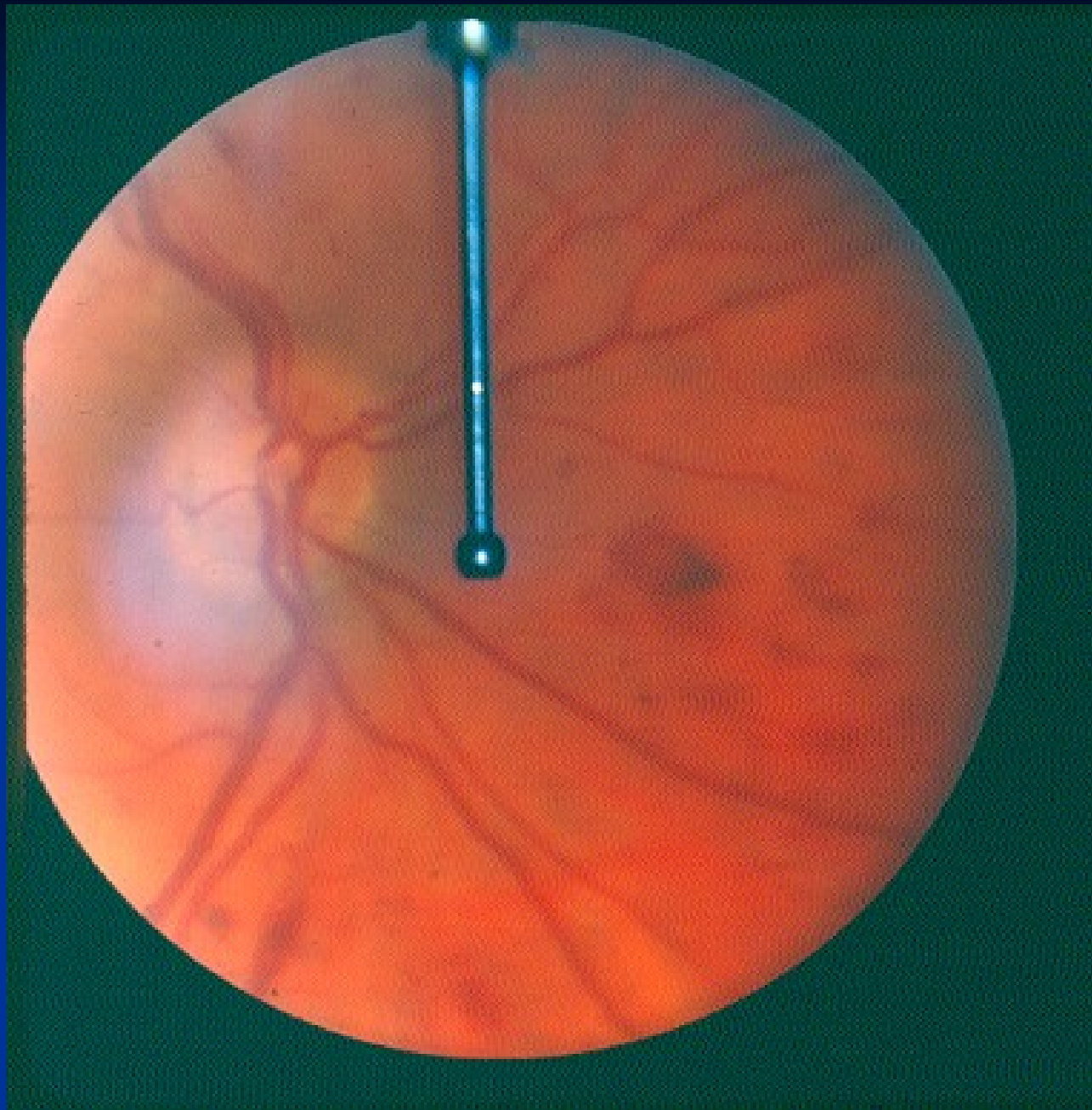
Proliferative Diabetic Retinopathy

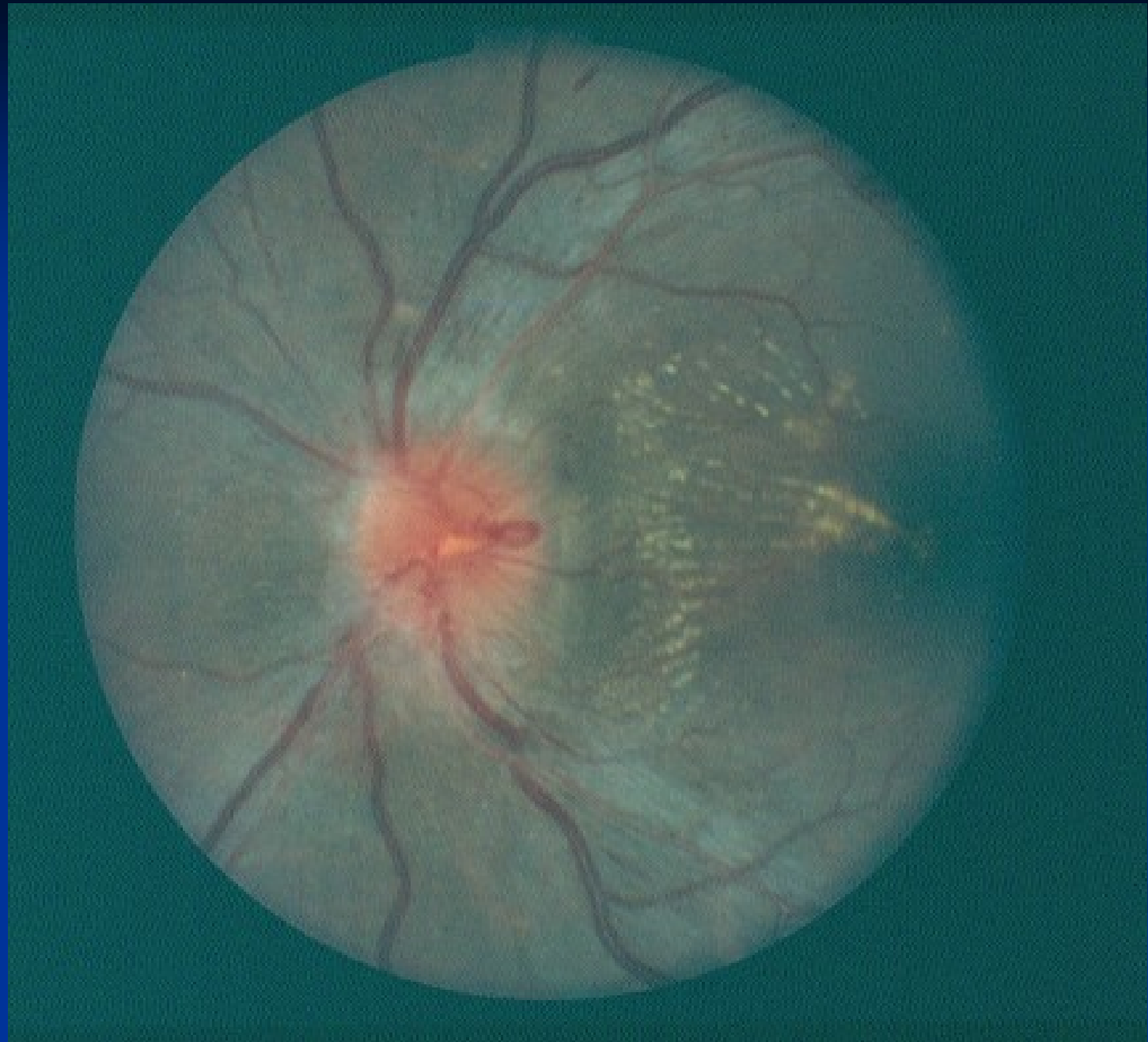- **Treatment**
 - Focal and PRP laser
 - Anti-veg F drugs
 - Avastine, Lucentis, Steroids

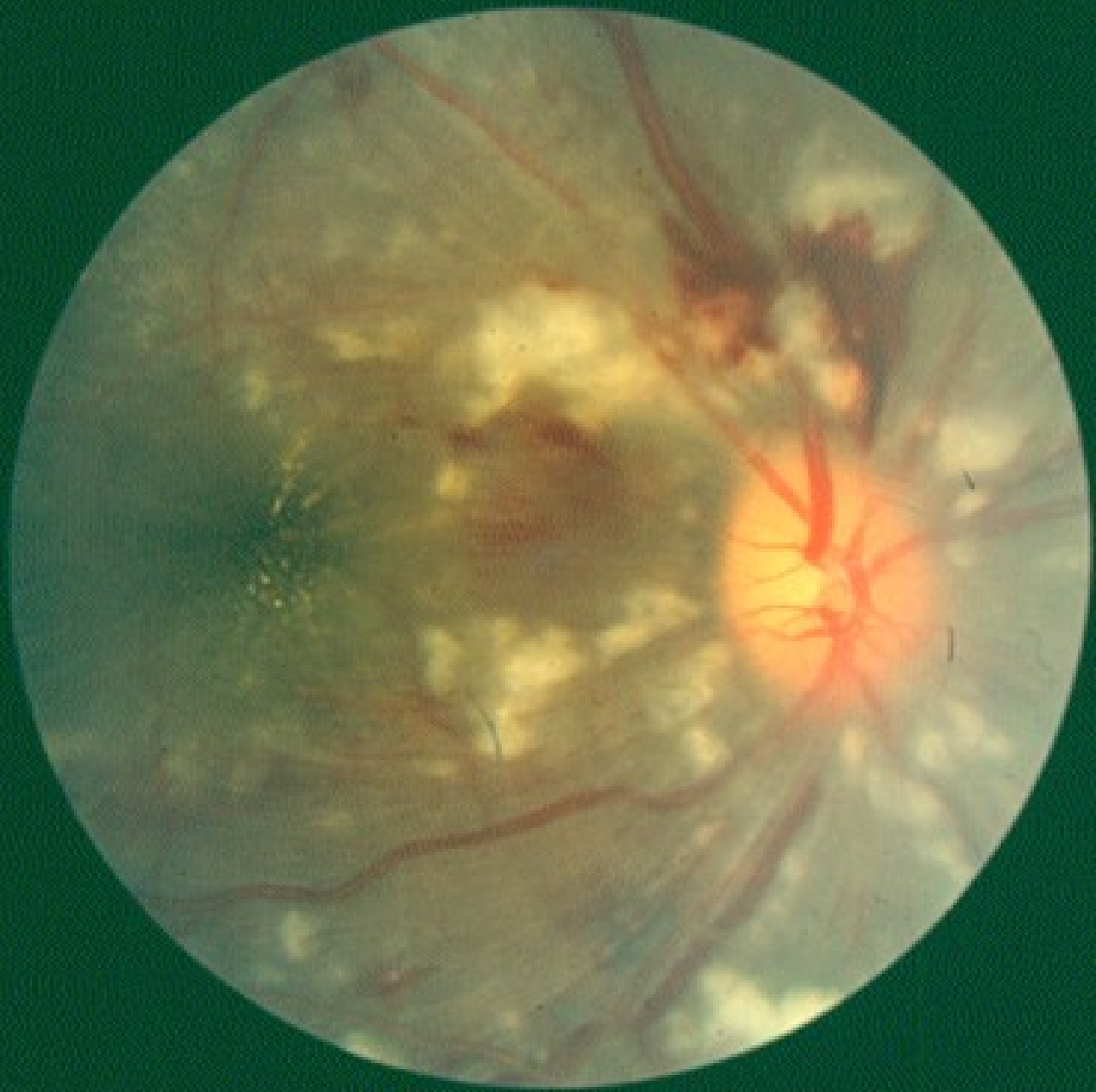

Hypertensive Retinopathy

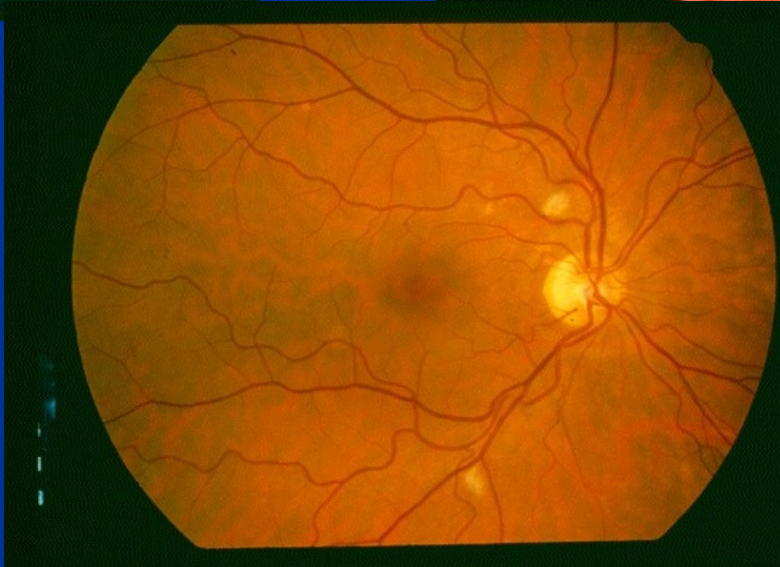
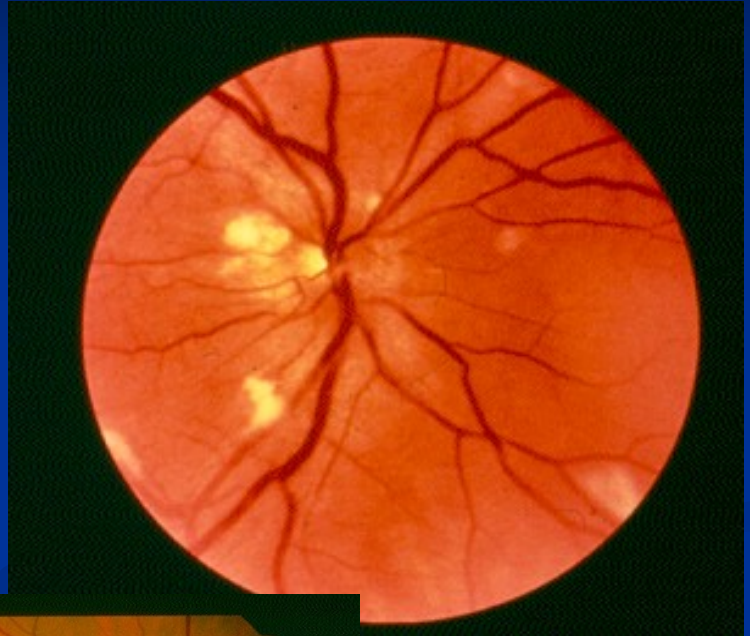
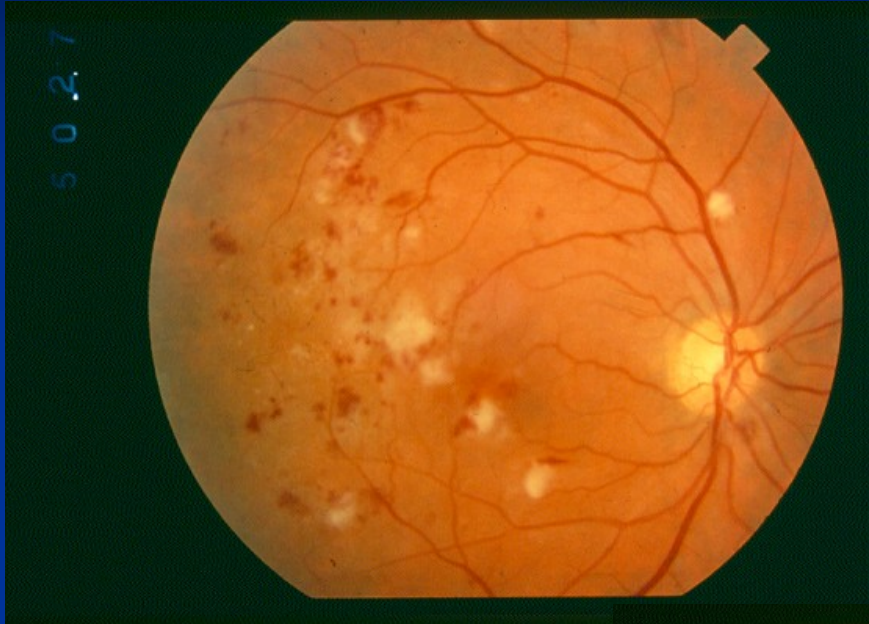



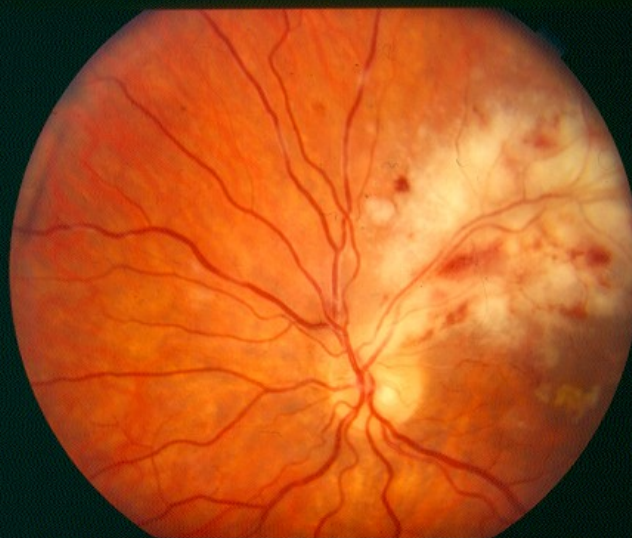

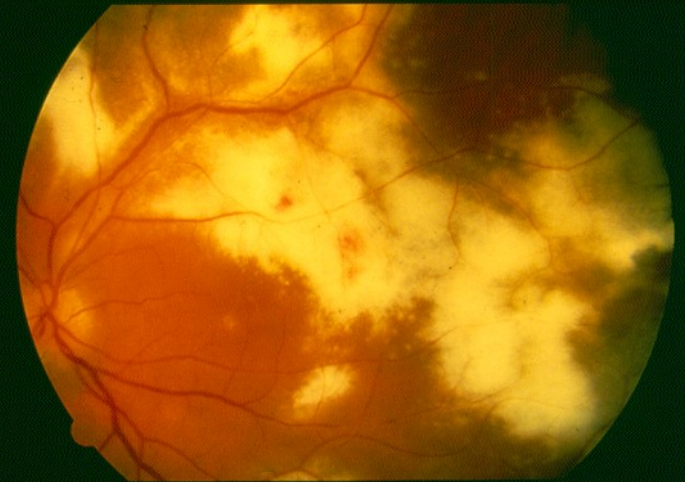
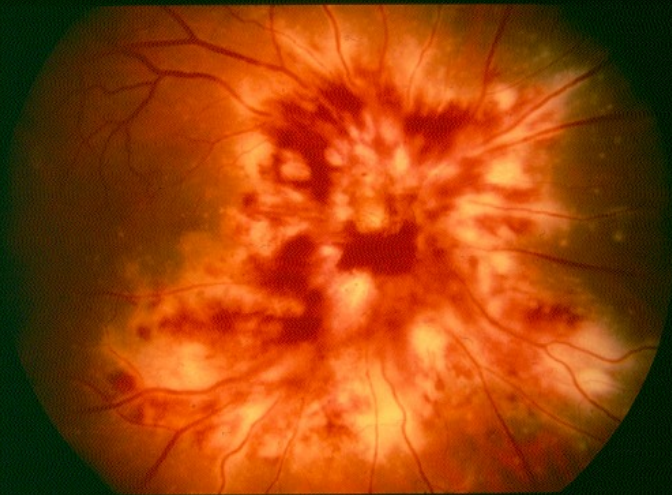

What is the diagnosis?



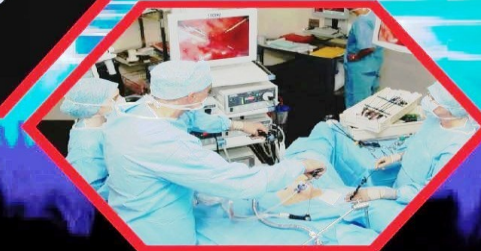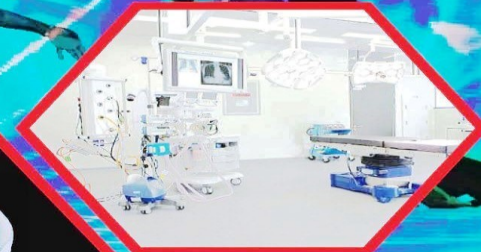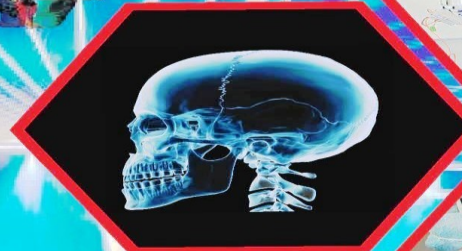Clue....



Q & A

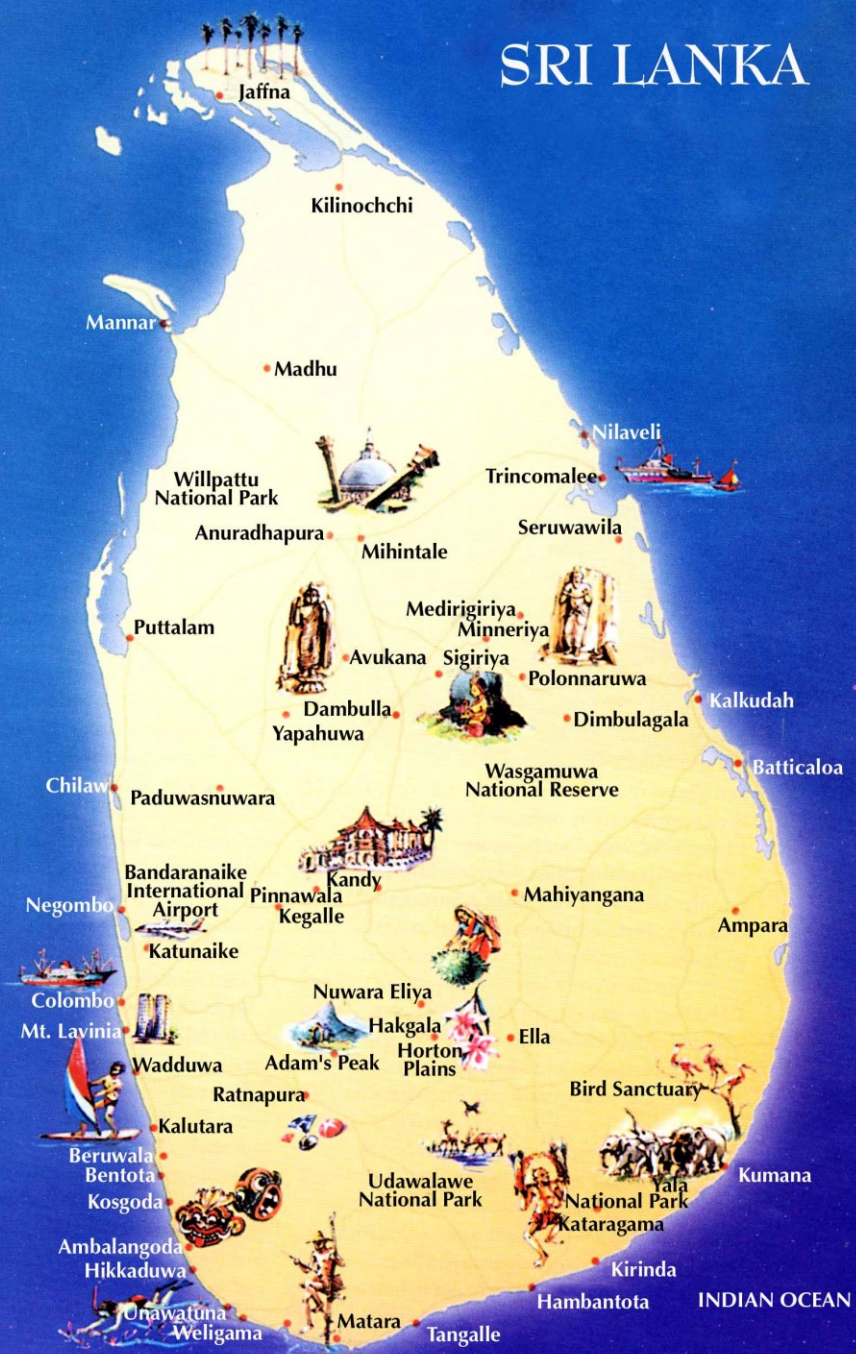ANKA MEDICAL ASSOCIATION OF NORTH AMERICA
EASTERN REGION INC.
PRESENTS

**SLMANA EAST
CHARITY BALL
ANNUAL GENERAL MEETING
&
SCIENTIFIC SESSIONS
ON
NOVEMBER 12TH, 2011**



NEW YORK HILTON AND TOWERS
1335 Avenue of The Americas New York, NY

SRI LANKA



**SURGICAL OPTIONS
FOR
END-STAGE HEART
DISEASE**

**Niloo M. Edwards, M.D.
Chief Cardiac & Vascular Services
St. Peter's Hospital, Albany NY**



CHRISTIAAN
BARNARD

ONE
LIFE

BY
DR. CHRISTIAAN BARNARD
& CURTIS BILL PEPPER

Louis Washkansky (December 12th 1967)



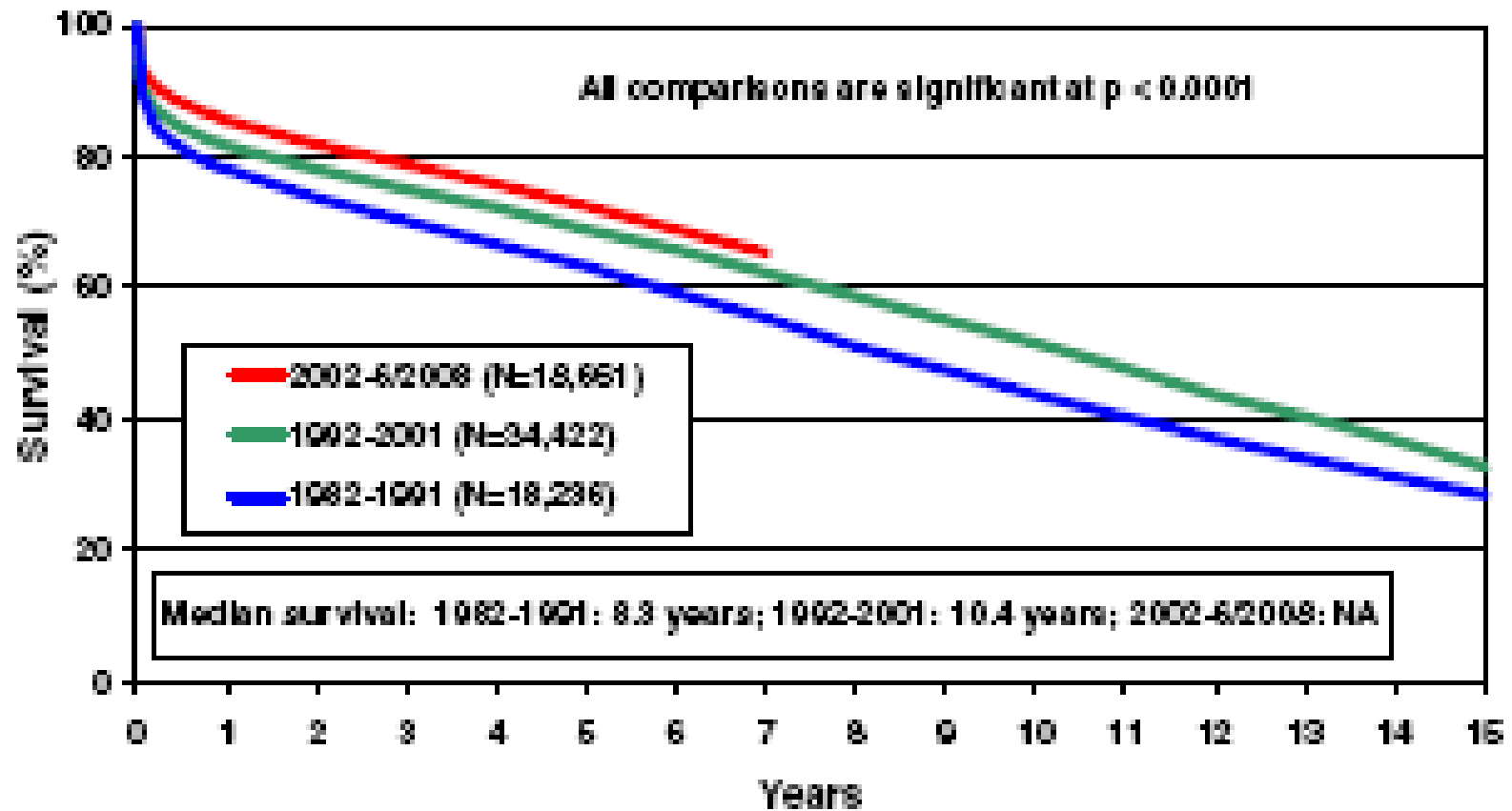
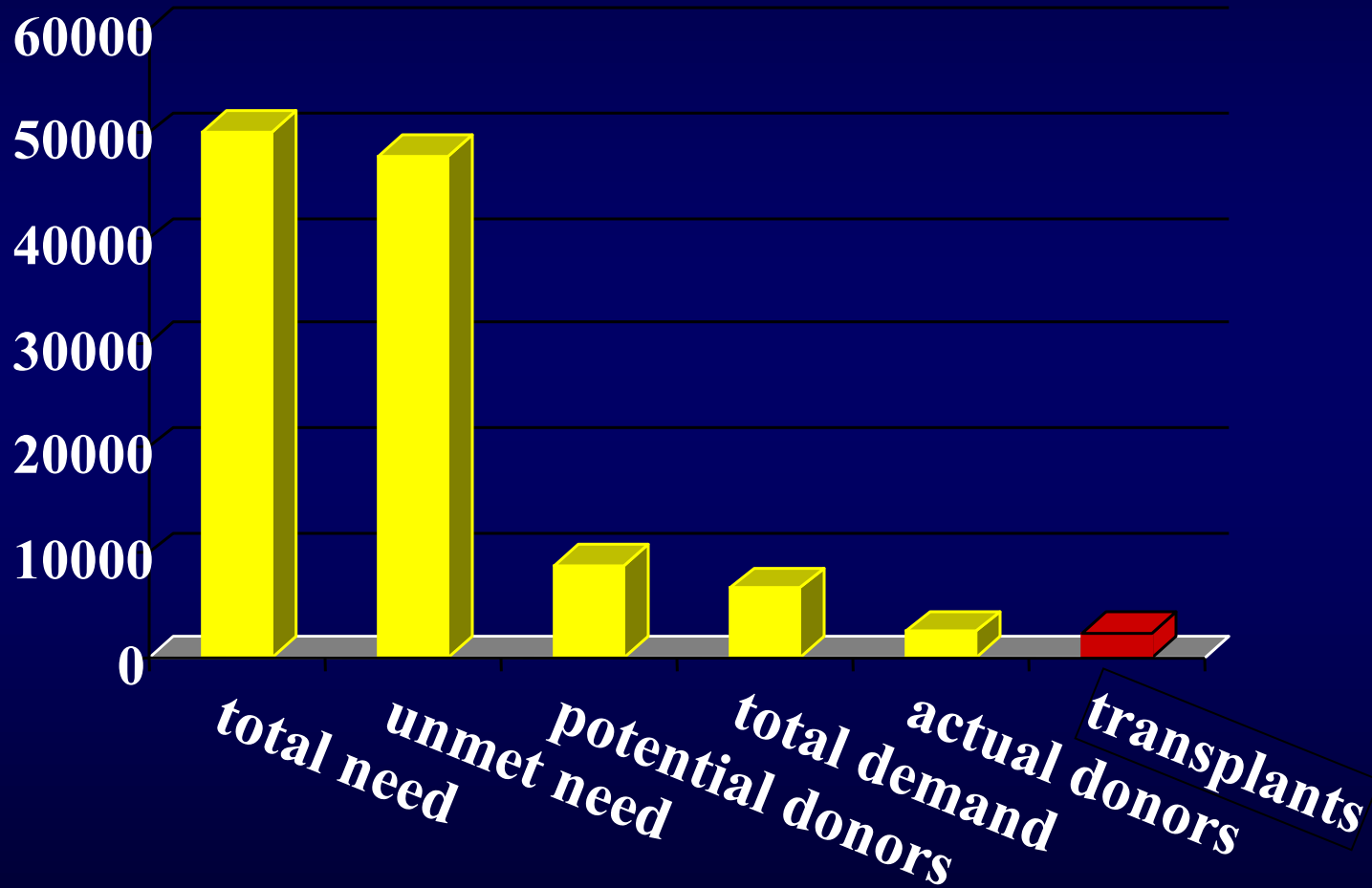
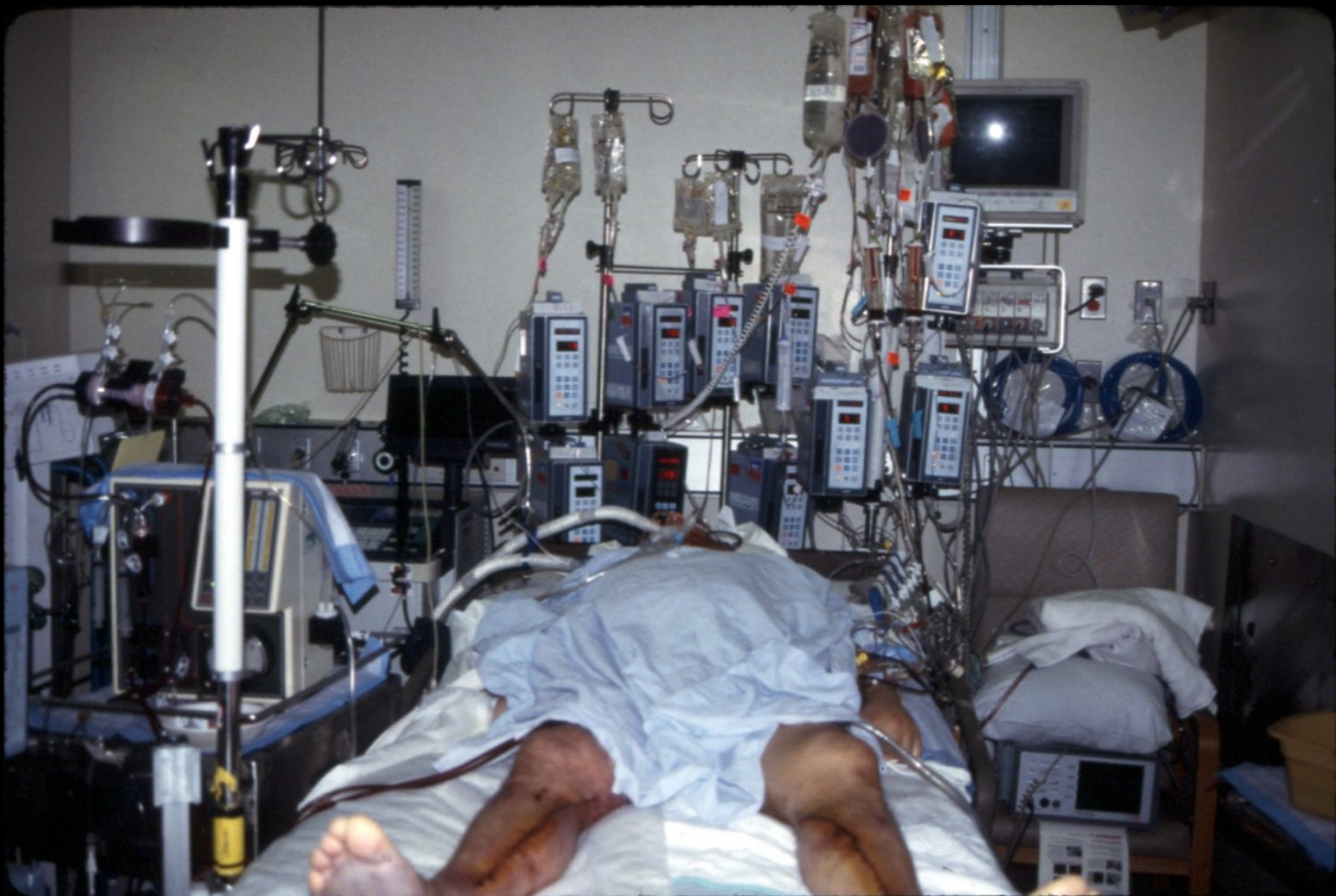

Figure 10 Survival for adult heart transplants performed between January 1982 and June 2008, stratified by era of transplant. NA, not available.

Heart Transplant Need





Prim and proper teacher's transplant shocker!

My new heart turned me into a beer-guzzling clod

A lady schoolteacher says the man's heart she got in a transplant operation has turned her into a beer-chugging, cigar-smoking, pro wrestling fanatic, European newspapers report.

"They might as well have given me a sex change," Christina Laurent, 45, told reporters from her home in Avignon, France.

Cops can't make drunks say ABCs

Cops will have to read tipsy drivers their rights before having them write the alphabet during roadside sobriety tests, according to a wacky new court ruling.

A Pennsylvania court of appeals ruled that officers may require drivers to perform physical tasks such as walking in a straight line without advising them of their constitutional rights.

But the court said Miranda warnings are necessary before "testimonial evidence," including reciting the alphabet.

"Before the operation I was a refined woman, with a woman's interests and a woman's desires. Now I'm not happy with a good book and a glass of wine.

"I'm not satisfied unless I have a beer in my hand, a cigar in my mouth and professional wrestling on TV. I'm not saying I'm not grateful to be alive.

"But my husband is threatening to divorce me — he says this new heart has turned me into a clod!"

"Clod isn't the word for it," fumed Andre Laurent, her husband of 23 years. "She stinks up the house with those cigar smoke and beer breath

Docs give her a man's heart — now she puffs stogies and rants and raves at TV wrestlers

like a common sot. But it's the wrestling that really gets me. She rants and raves like a lunatic when it's on and then analyzes it for hours when it's over.

"I'm sick of it. If she doesn't straighten up soon I really will get a divorce."

Laurent fears the change in his wife's behavior is an irreversible condition caused by the truck driver's heart that replaced her own worn-out ticker.

Transplant surgeon Charles

woman has been a different person since her operation last December.

But he called the charges "a typical and transient psychological response" to the transplant, nothing more, nothing less.

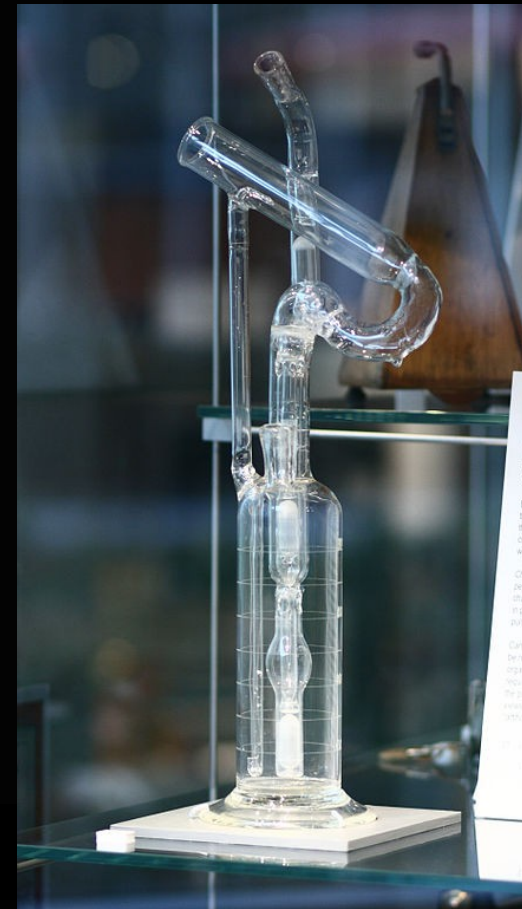"It's not at all uncommon for these patients to suffer identity crises after their operations," he said.

"These crises are usually fleeting, however, and I'm sure she'll come around in time."



HEART surgery has ruined Christina Laurent's life.

soon enough for me," said Laurent. "She's already gearing up for a big wrestling extravaganza that's coming to



Types of Ventricular Assist Devices - VADs

Mechanical Circulatory Assistance

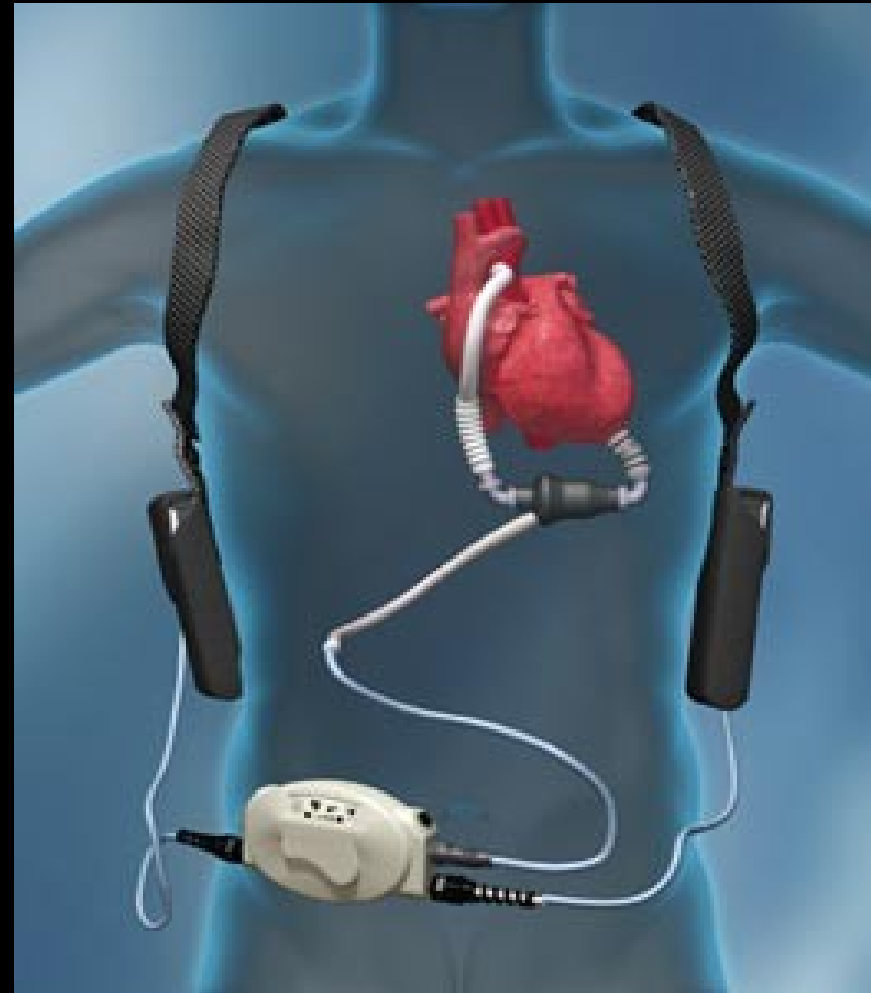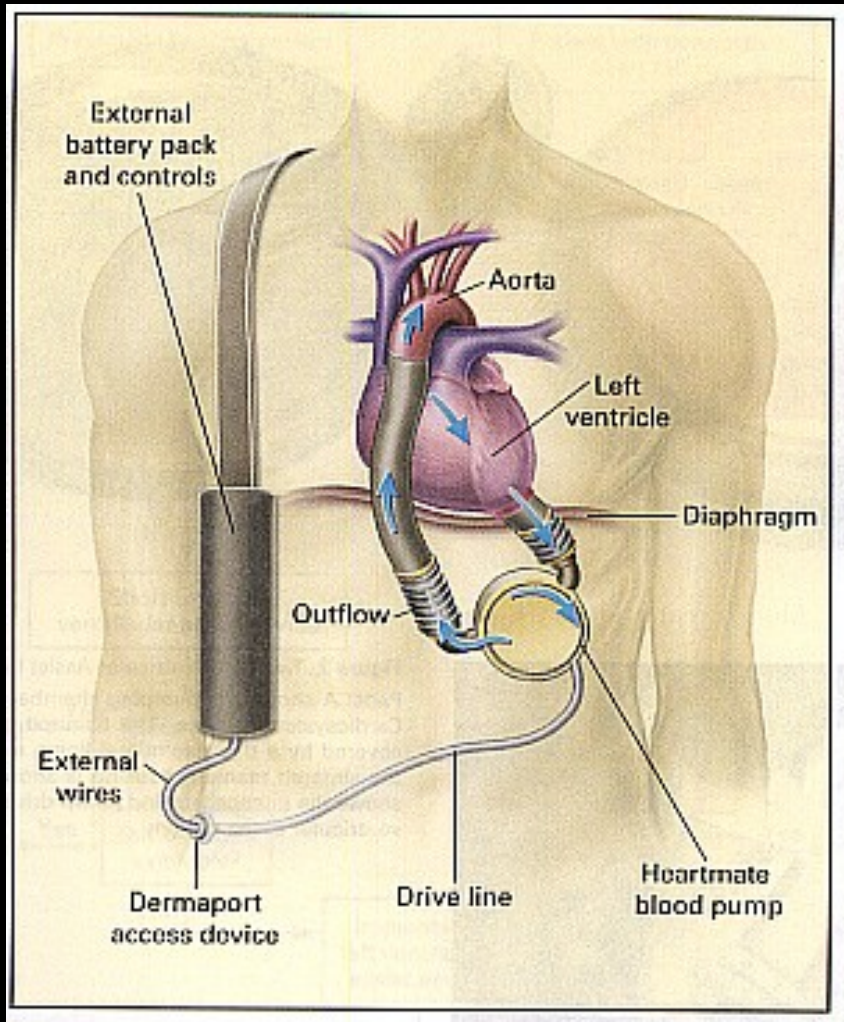
◆ Short term devices



- IABP
- Adult ECMO
- Percutaneous LVAD (TandemHeart)
- Abiomed LVAD, RVAD, BiVAD
- Centrimag



Implantable VADs



Pulsatile vs. Non-pulsatile

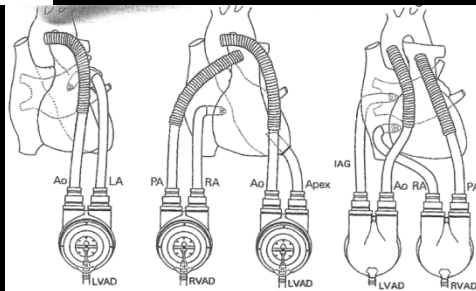
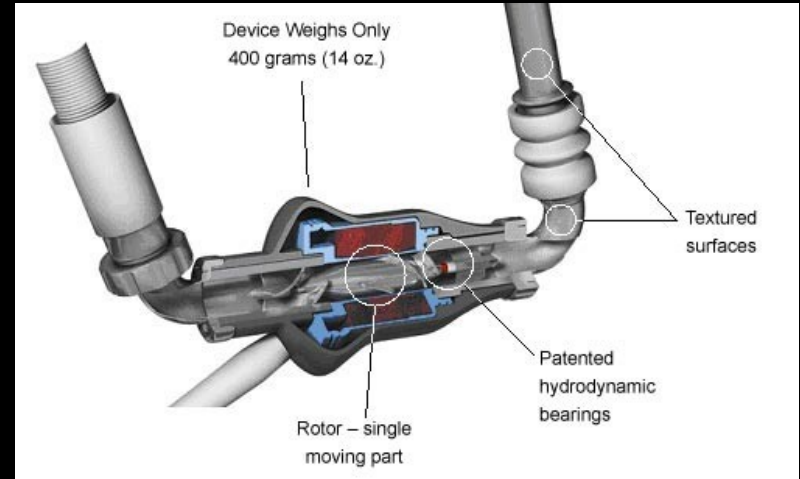
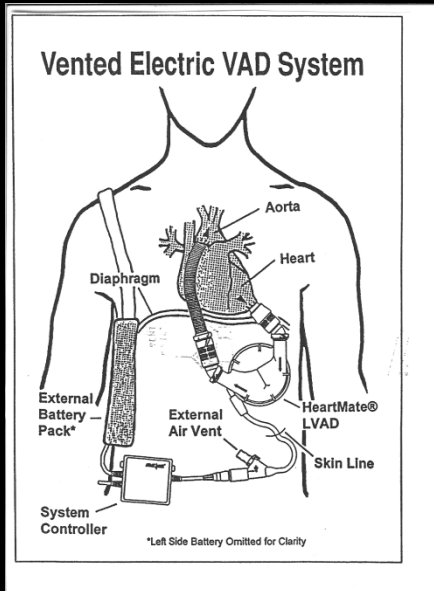


Figure 1.1 Cannulation Approaches for the Thoratec® VAD

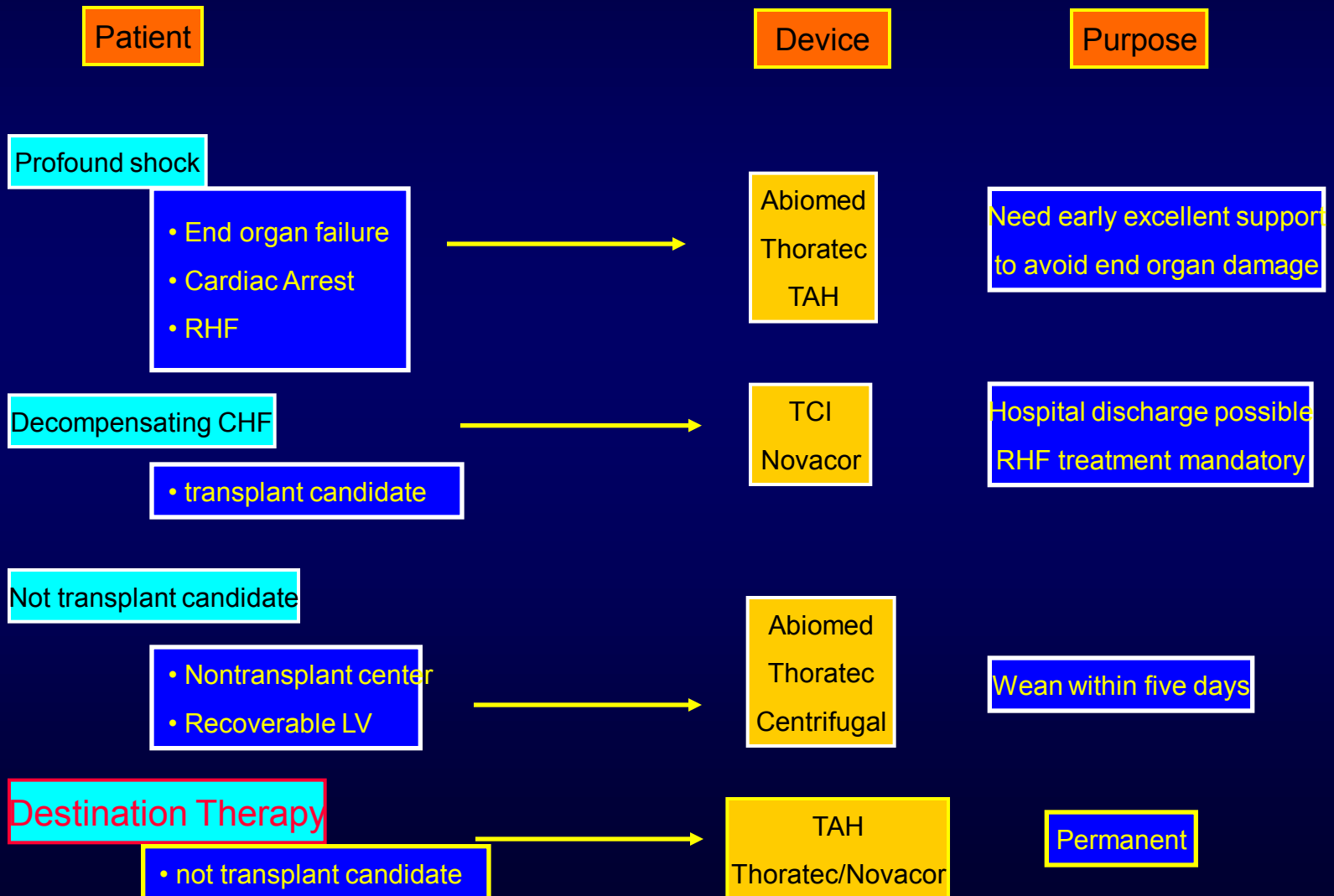
A. Univentricular left heart support; B & C. Biventricular support
 (Ao = aorta, LA = left atrial appendage,
 PA = pulmonary artery, RA = right atrium, Apex = left ventricular apex,
 IAG = cannula inserted via the interatrial groove and directed towards the LA roof.)
 (Modified from Farrar DJ et al: New England Journal of Medicine 1988; 318:333-340.
 Copyright 1988, Massachusetts Medical Society)



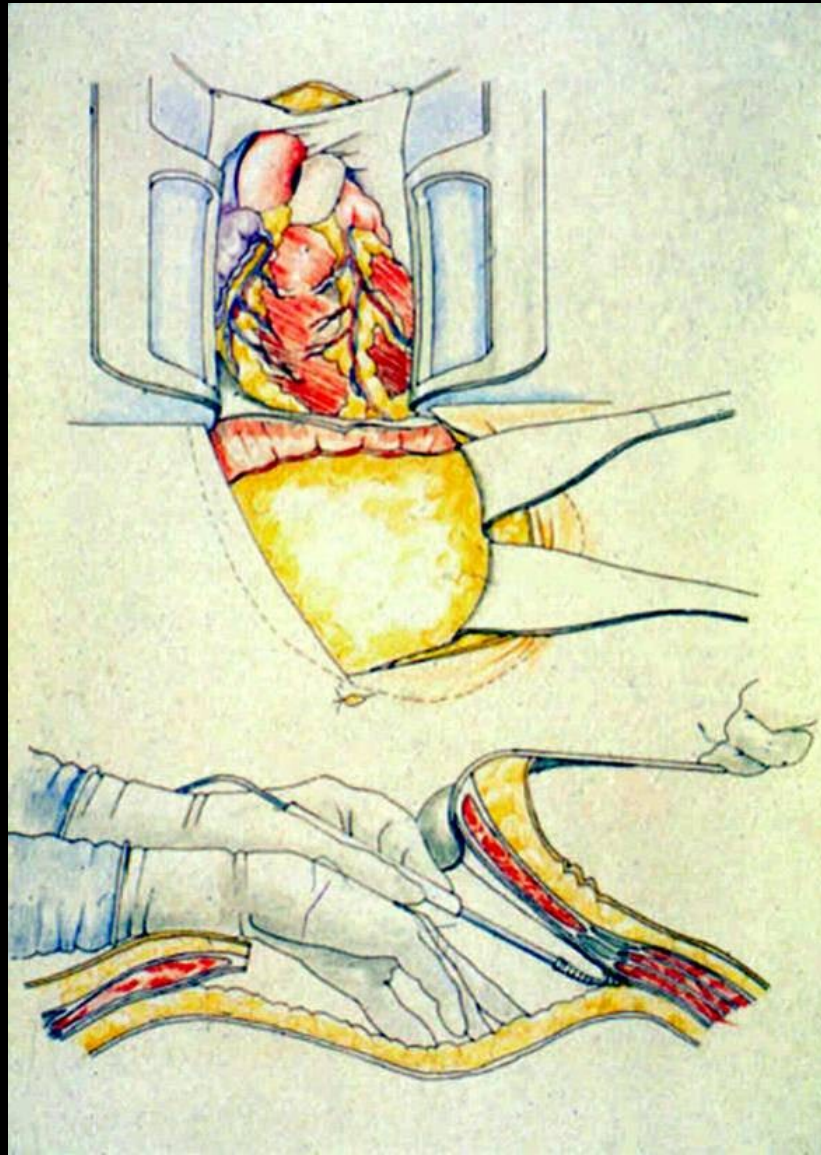
Ventricular Assist Devices

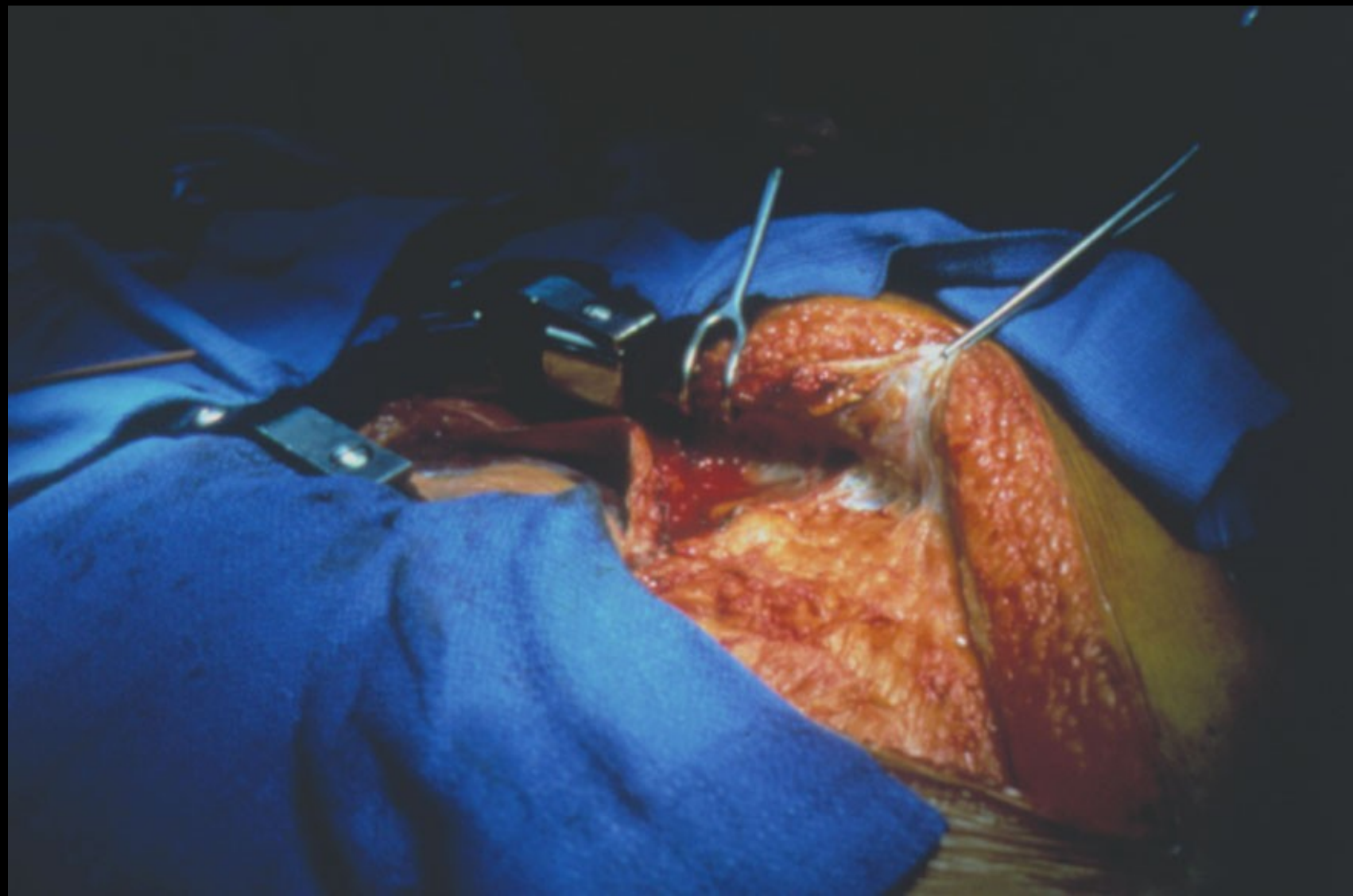
- ◆ Left ventricular assist device (LVAD)
- ◆ Right ventricular assist device (RVAD)
- ◆ Bi-ventricular assist device (BiVAD)

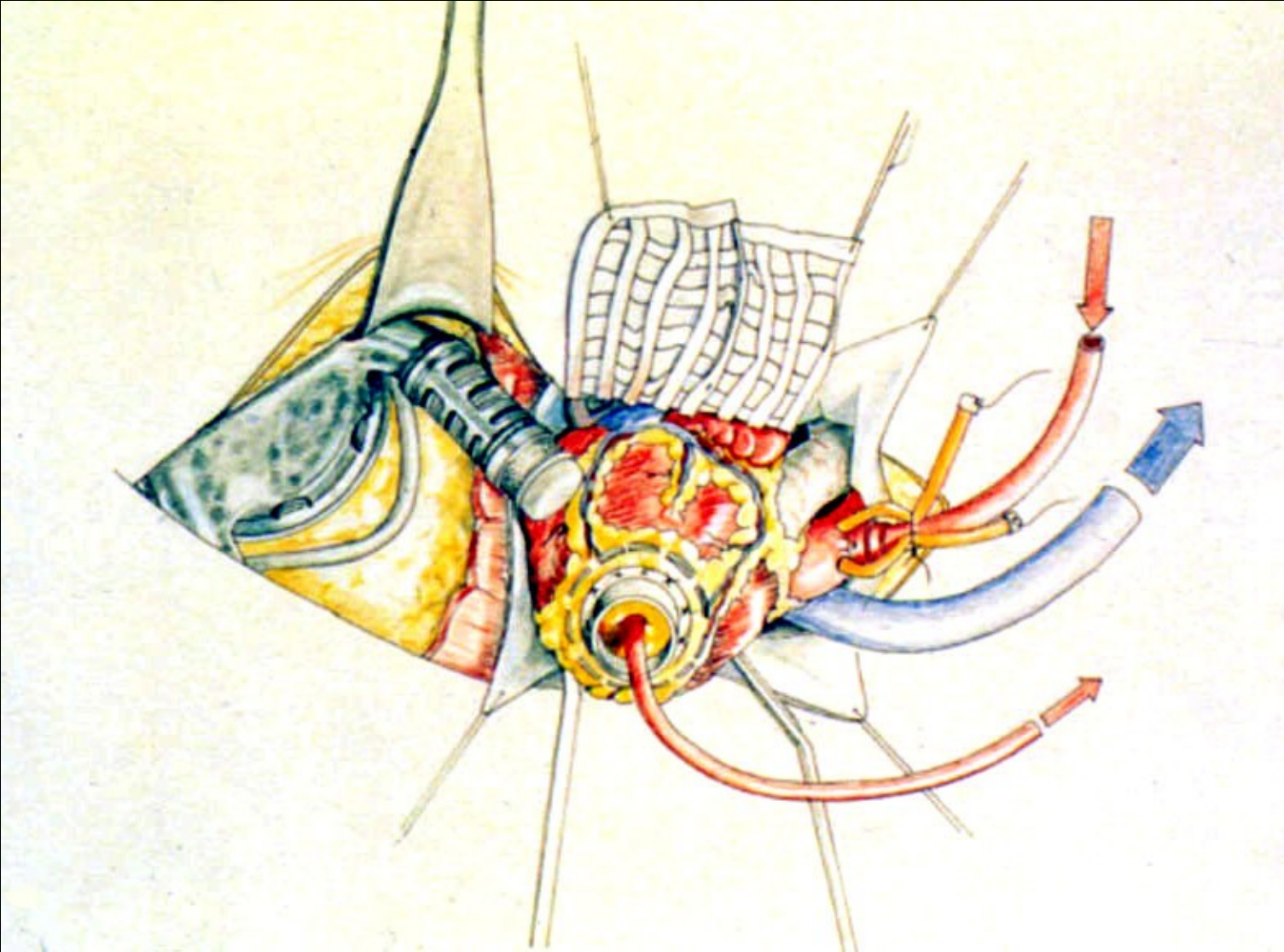
Type of VAD :patient's status and length of support

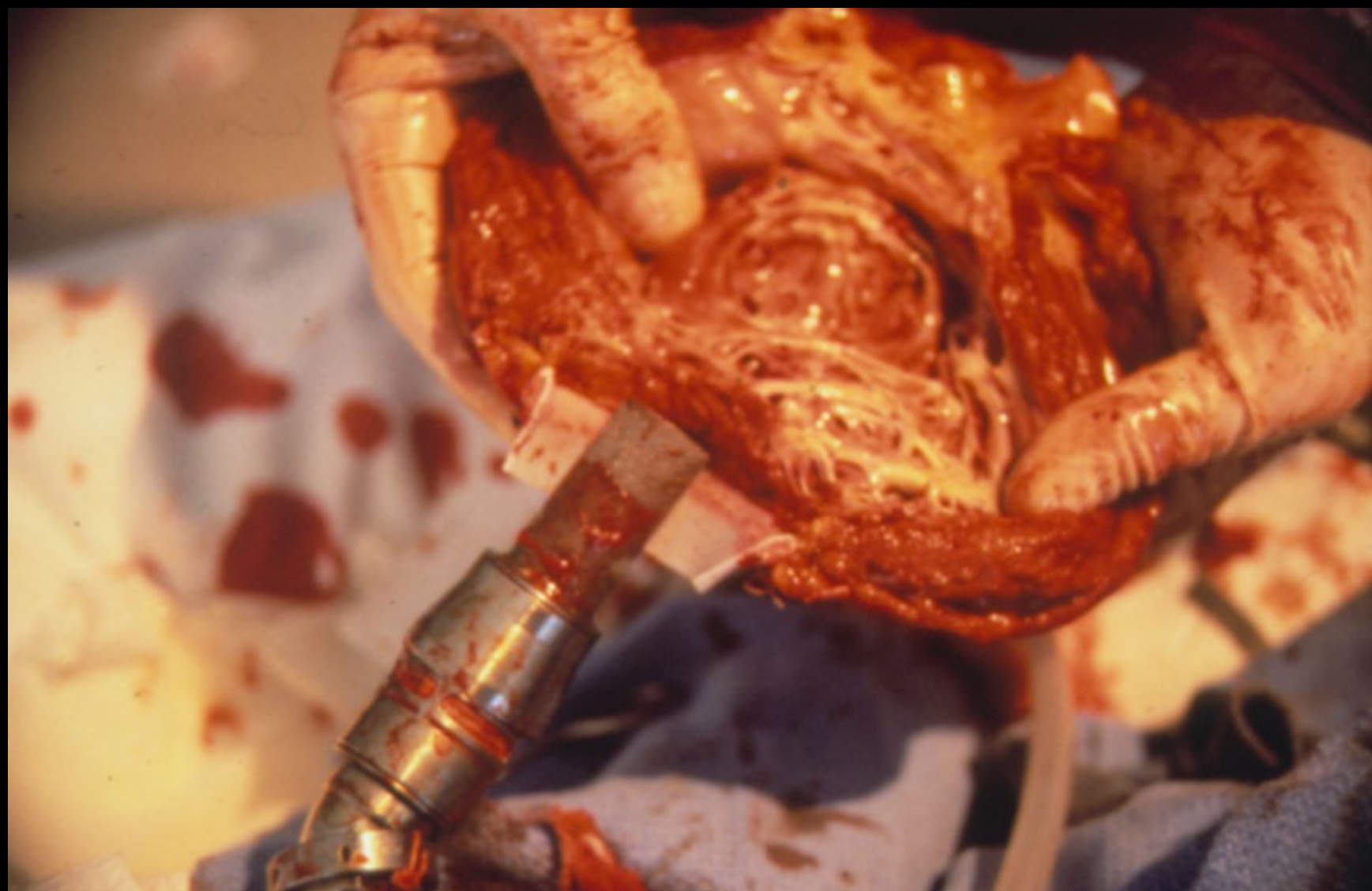

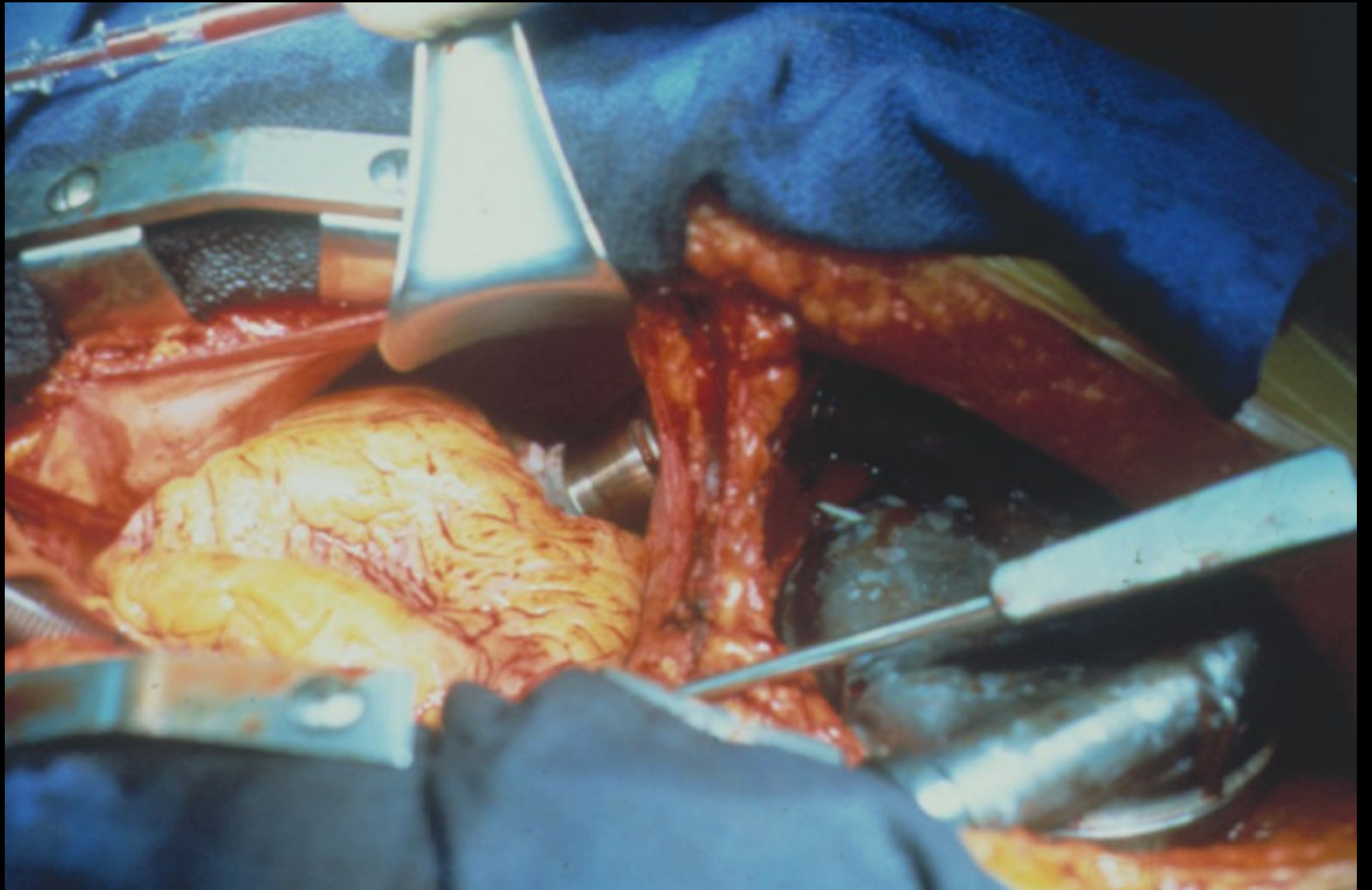


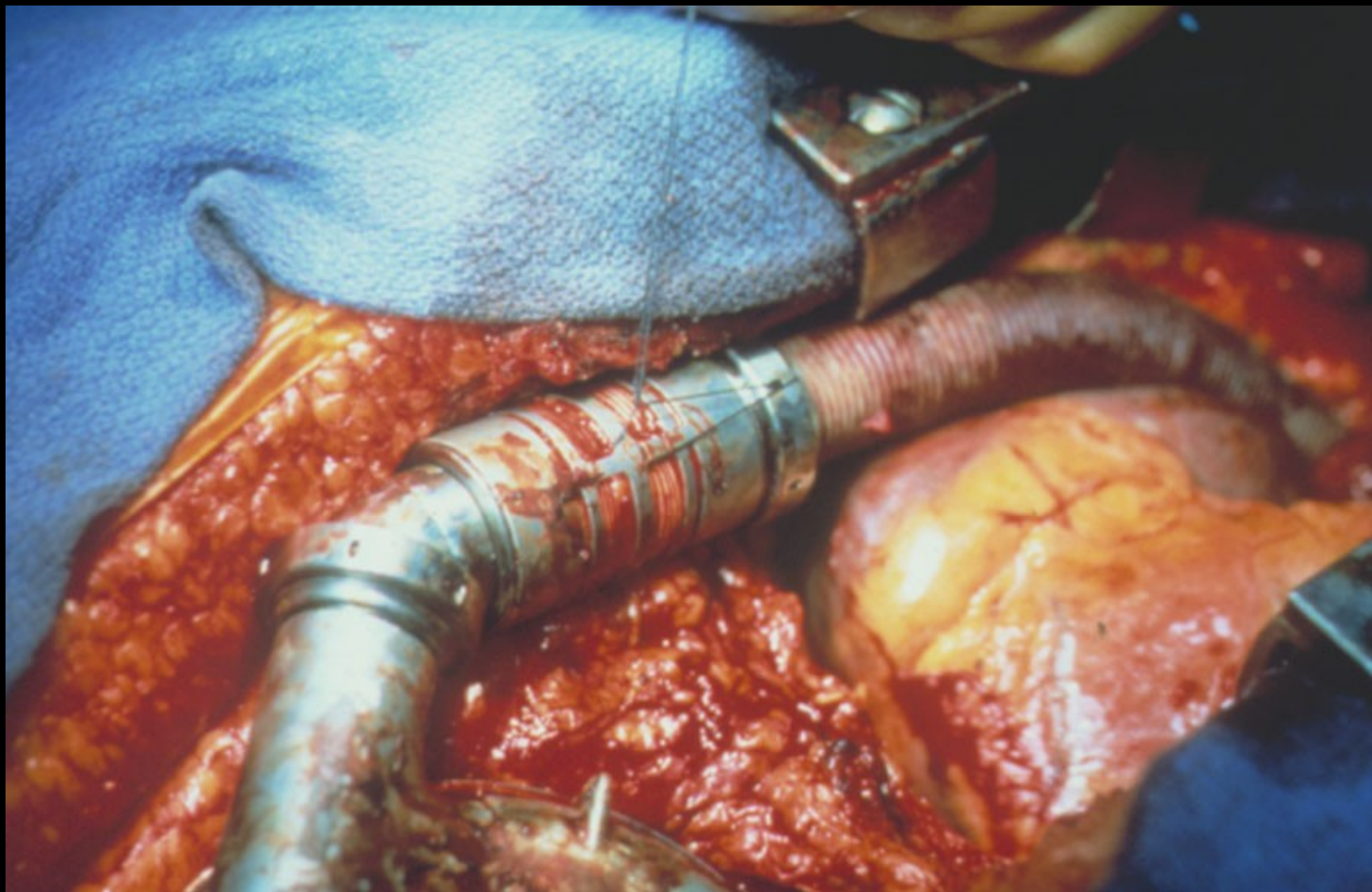














Current Role of VADs

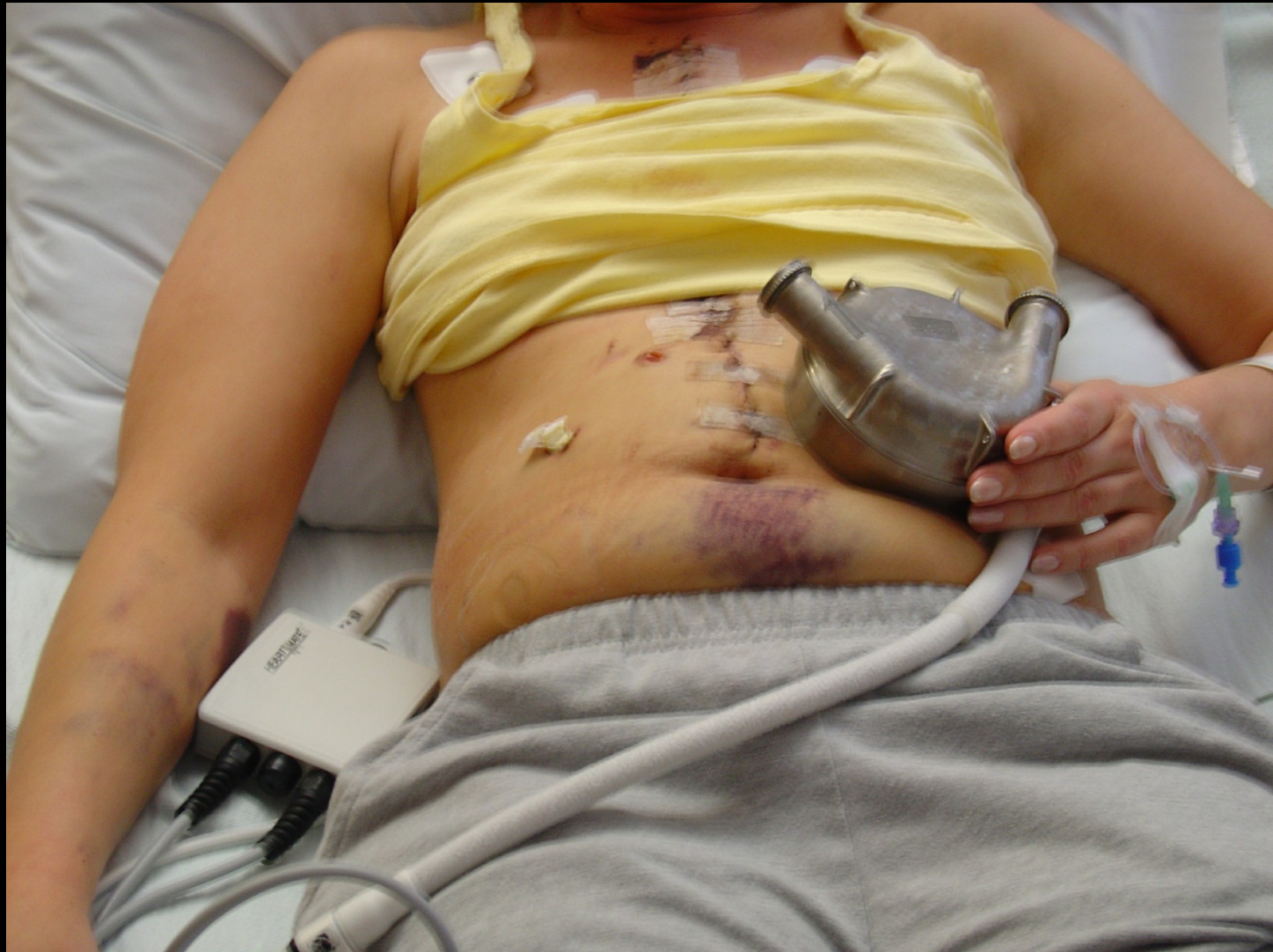- ◆ Bridge to transplantation
- ◆ Destination therapy
- ◆ Bridge to candidacy
- ◆ Bridge to recovery
- ◆ Backup for high risk reparative surgery

- ◆ Bridge to transplantation
- ◆ Destination therapy
- ◆ Bridge to candidacy
- ◆ Bridge to recovery
- ◆ Backup for high risk reparative surgery

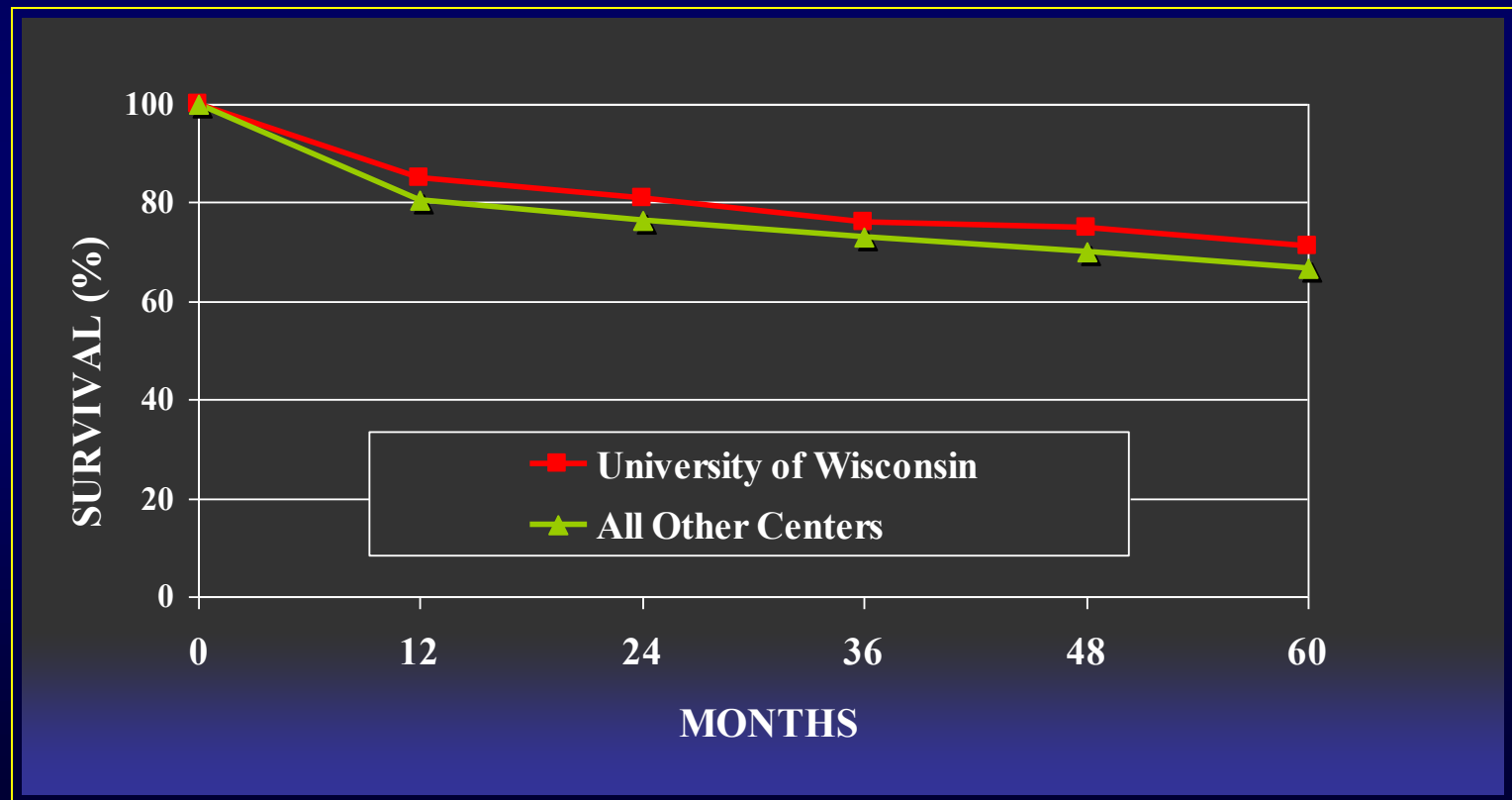


FAILURE


WHEN YOUR BEST JUST ISN'T GOOD ENOUGH.



group	30-day (95% CI)	1-year (95% CI)	2-year (95% CI)
Early (90-96)	84% (72-96%)	62% (47-72%)	49% (33-65%)
Mid (97-7/03)	71% (55-87%)	52% (34-69%)	42% (25-59%)
Late (8/03-8/06)	100%	86% (66-99%)	81% (65-97%)

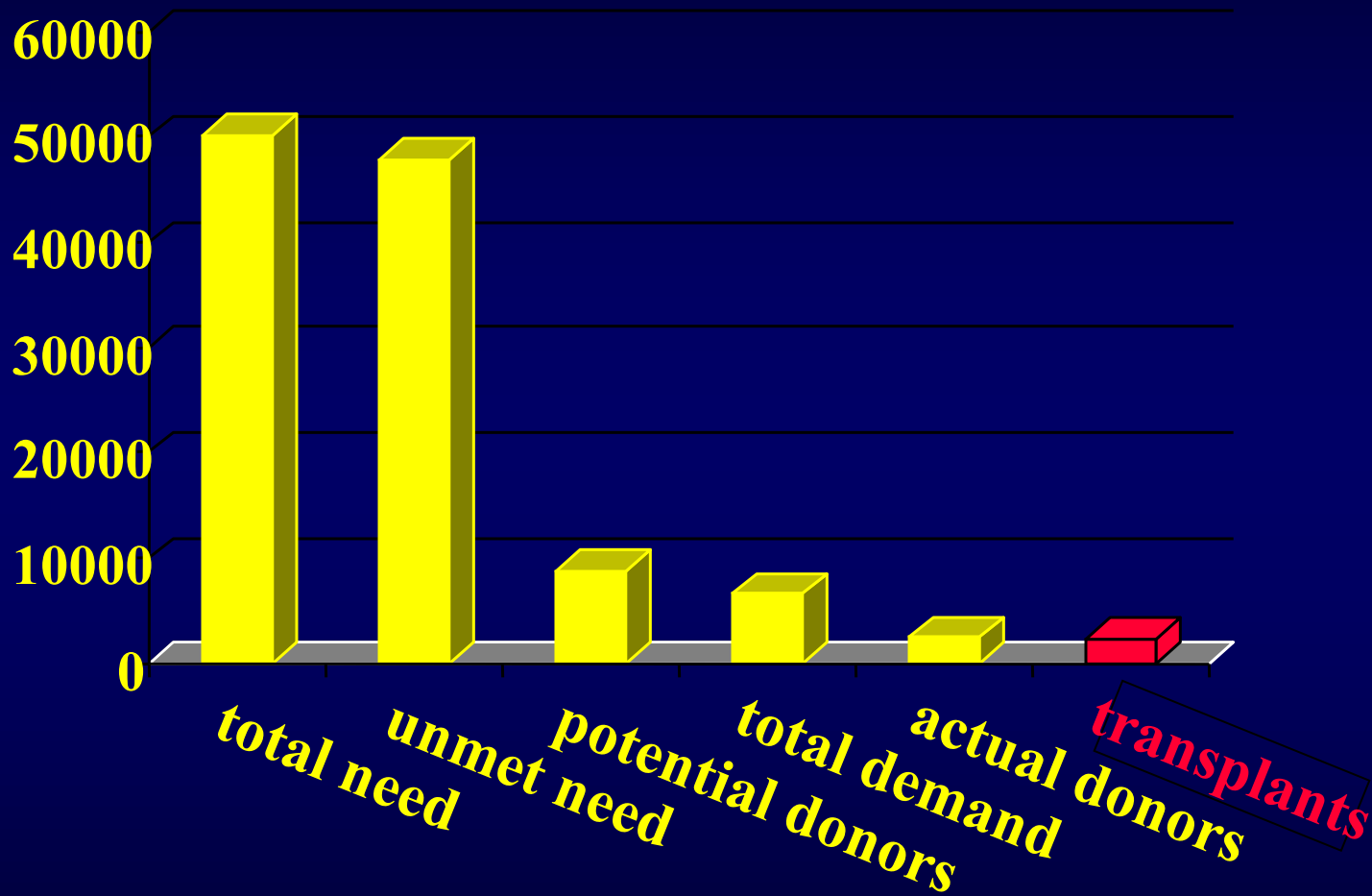


- ◆ Bridge to transplantation
- ◆ Destination therapy
- ◆ Bridge to candidacy
- ◆ Bridge to recovery
- ◆ Backup for high risk reparative surgery



**“Well, lemme think. ... You’ve stumped me, son.
Most folks only wanna know how
to go the other way.”**

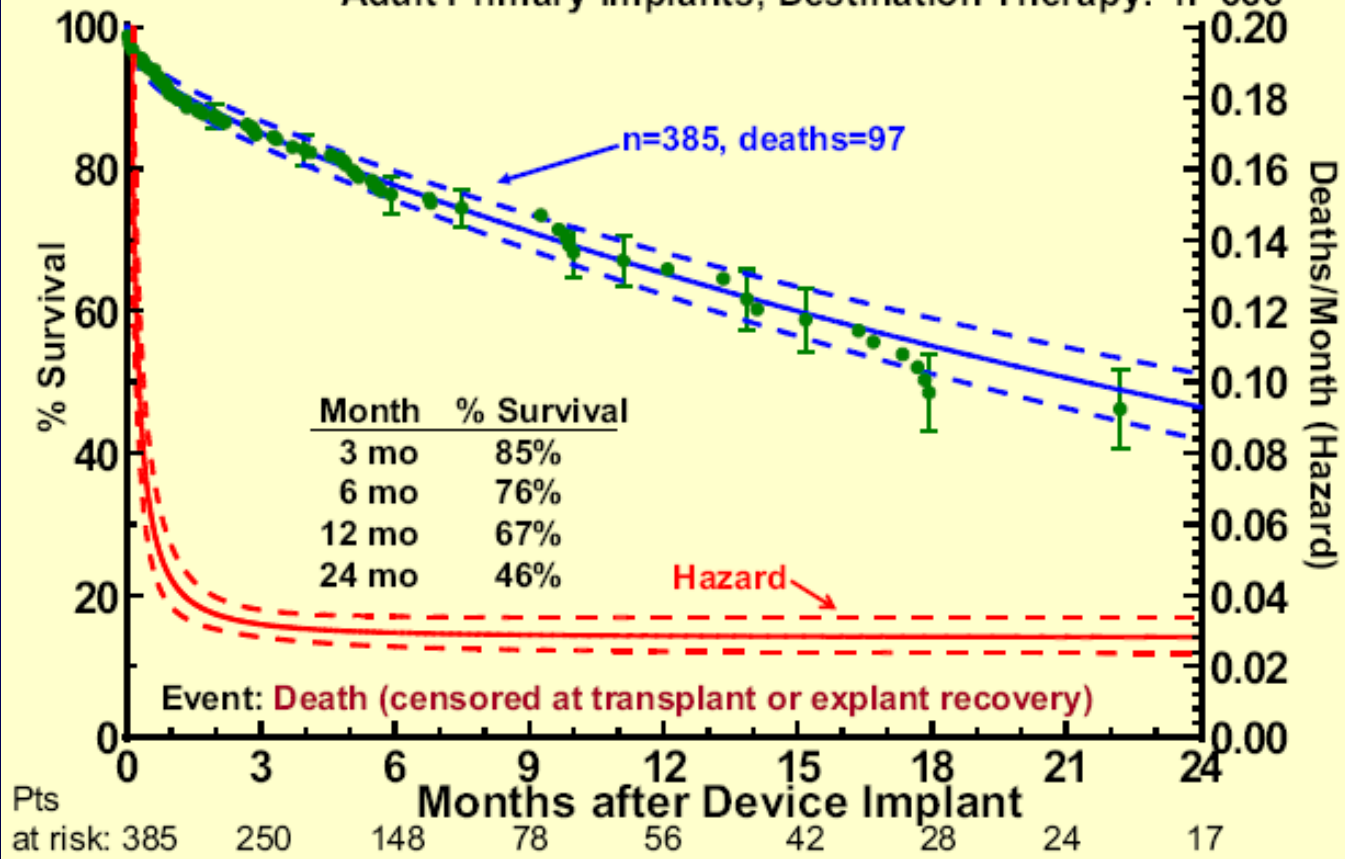
Need



Overall Survival

intermacs: June 2006 – September 2010

Adult Primary Implants, Destination Therapy: n=385



- ◆ Bridge to transplantation
- ◆ Destination therapy
- ◆ Bridge to candidacy
- ◆ Bridge to recovery
- ◆ Backup for high risk reparative surgery

According to repeated nationwide surveys,

More Doctors Smoke **CAMELS** than any other cigarette!



Doctors in every branch of medicine were asked, "What cigarette do you smoke?" The brand named most was Camel!

You'll enjoy Camels for the same reasons so many doctors enjoy them. Camels have cool, cool *mildness*, pack after pack, and a *flavor* unmatched by any other cigarette. Make this sensible test: Smoke only Camels for 30 days and see how well Camels please your taste, how well they suit your throat as your steady smoke. You'll see how enjoyable a cigarette can be!

THE DOCTORS' CHOICE IS AMERICA'S CHOICE!



BARBARA STANWICK says: "I like Camels. They burn with an throat and taste wonderful!"



DICK POWELL says: "I got more pleasure from Camels than from any other brand."



HUGH DOWNS says: "Camels are my taste and throat. I've smoked 'em for years!"



For 30 days, test Camels in your "I-Zone" (I for Throat, I for Taste).

Exclusion Criteria

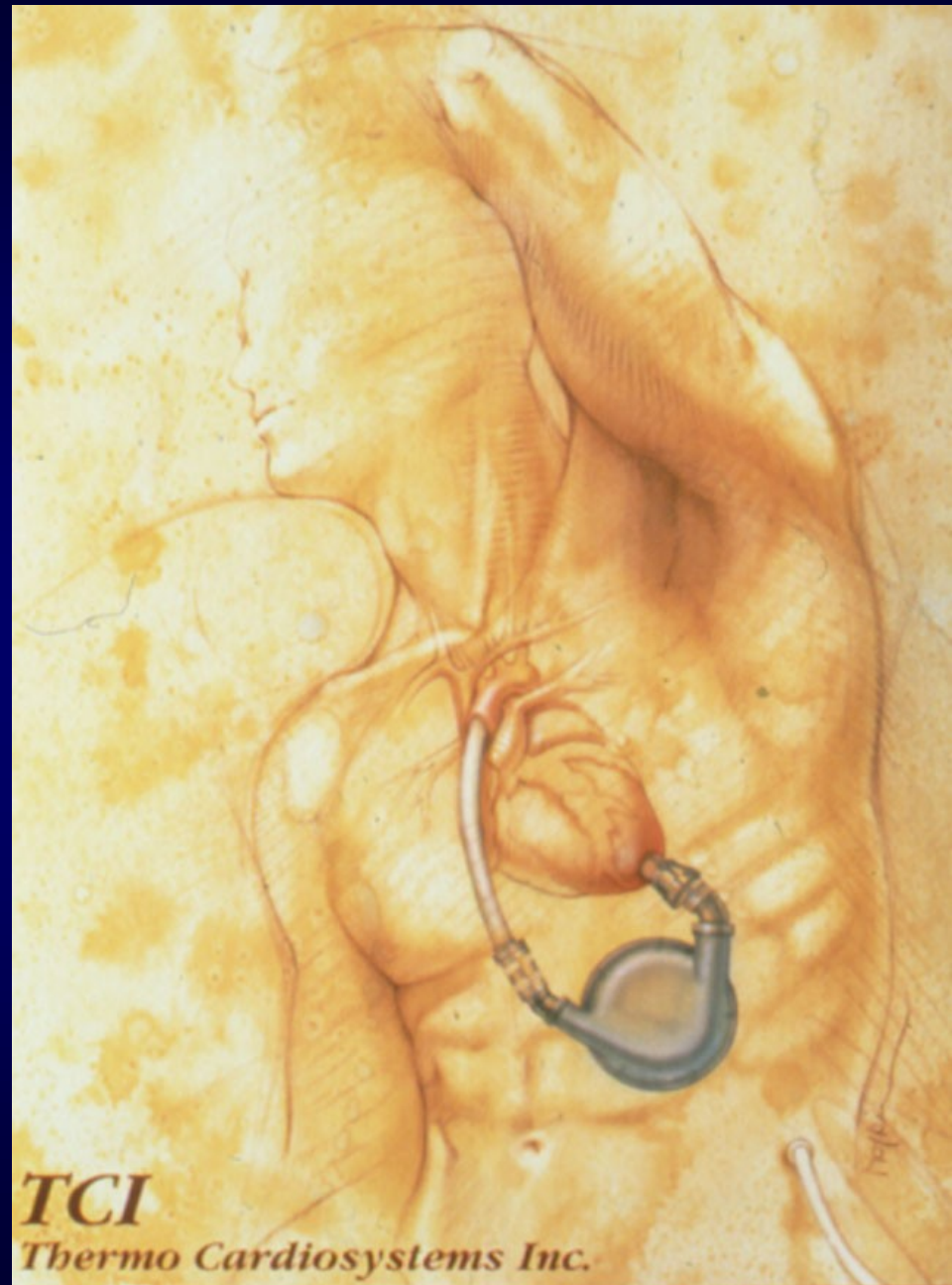Compliance problems

- ◆ Substance abuse
- ◆ Untreated psychiatric dz.

Perioperative risk factors

- ◆ Active peptic ulcer disease
- ◆ Morbid obesity/ cachexia
- ◆ Pulmonary embolus (<6wks)
- ◆ PVR > 6 WU

- ◆ Bridge to transplantation
- ◆ Destination therapy
- ◆ Bridge to candidacy
- ◆ **Bridge to recovery**
- ◆ Backup for high risk reparative surgery





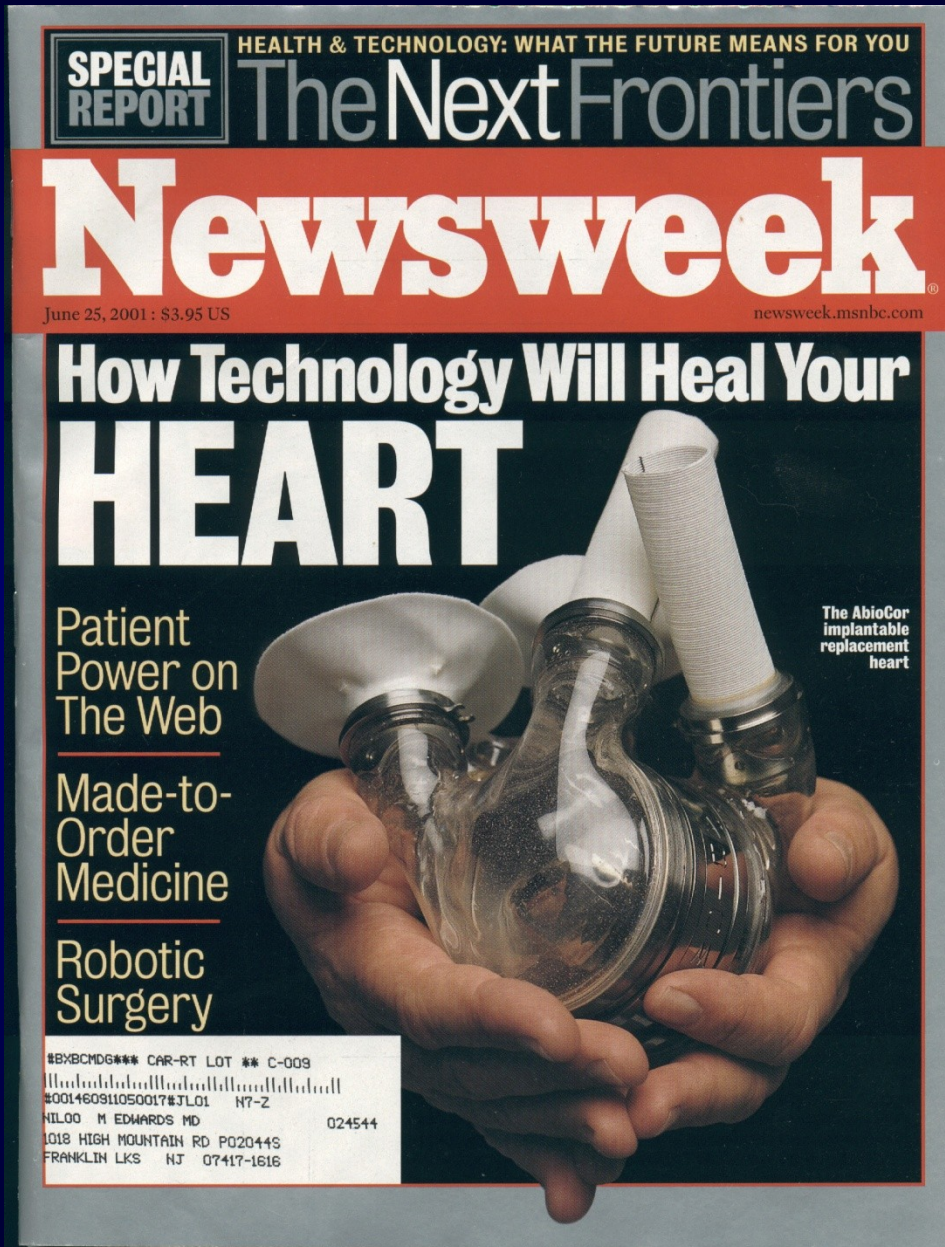The NEW ENGLAND
JOURNAL of MEDICINE

Volume 355 November 2, 2006 Number 18

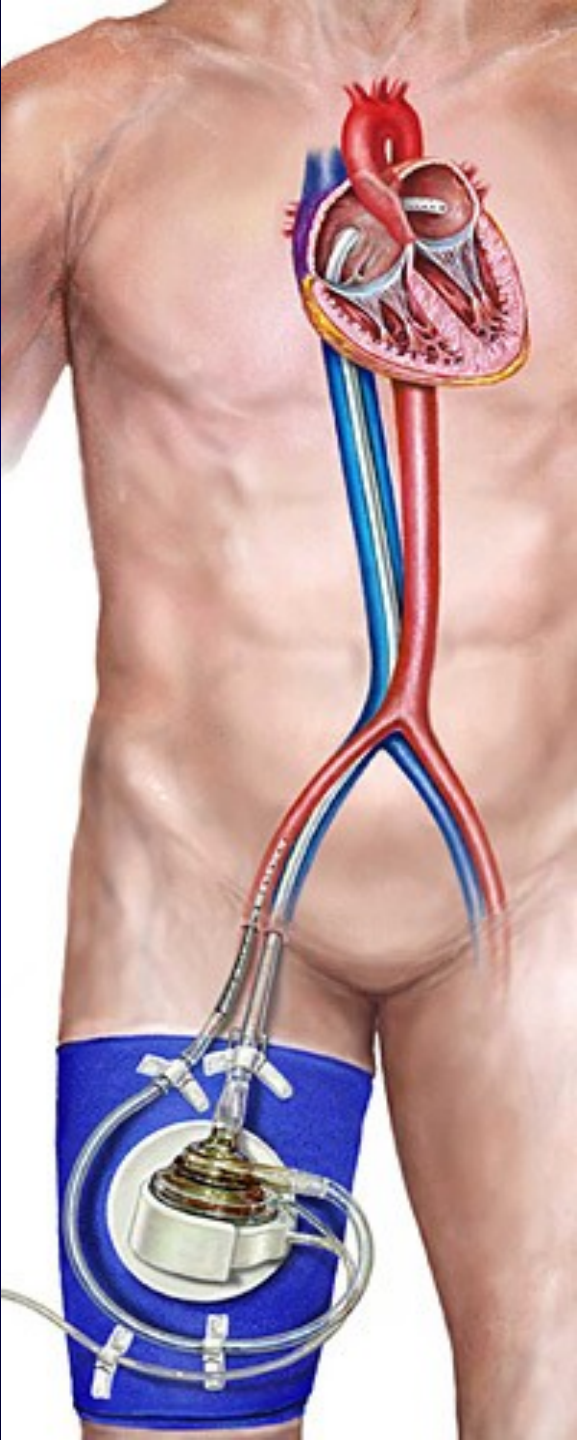
Left Ventricular Assist Device and Drug Therapy for the Reversal of Heart Failure

Emma J. Birks, M.R.C.P., Ph.D., Patrick D. Tansley, F.R.C.S., James Hardy, M.B., B.S., B.Sc., Robert S. George, M.R.C.S., B.Sc., Christopher T. Bowles, Ph.D., Margaret Burke, F.R.C.Path., Nicholas R. Banner, F.R.C.P., Asghar Khaghani, F.R.C.S., and Magdi H. Yacoub, F.R.S.

- ◆ Bridge to transplantation
- ◆ Destination therapy
- ◆ Bridge to candidacy
- ◆ Bridge to recovery
- ◆ Backup for high risk reparative surgery



Tandem Heart
External Support



© Original Artist

Reproduction rights obtainable from
www.CartoonStock.com





Q & A

ANKA MEDICAL ASSOCIATION OF NORTH AMERICA
EASTERN REGION INC.
PRESENTS

**SLMANA EAST
CHARITY BALL
ANNUAL GENERAL MEETING
&
SCIENTIFIC SESSIONS
ON
NOVEMBER 12TH, 2011**



NEW YORK HILTON AND TOWERS
1335 Avenue of The Americas New York, NY